



PATIENT PRESENTING CLINICAL SIGNS

Patient: Pippa West
History: About a 3 day history of facial focal seizures. Her teeth grind and her head leans to the side while her lips and face twitch. Each episode lasts about 20 seconds and she has had a total of about 5-6. On tapering dose of Prednisone from primary vet for skin allergies.

SPECIES: Abnormal PE/Chem/CBC/UA Results:
 Canine

COMPUTED TOMOGRAPHIC STUDY OF THE SKULL

BREED: A high resolution pre- and post-contrast CT study of the skull is provided for review.

Retriever Mix COMPUTED TOMOGRAPHIC FINDINGS

SEX: Both temporomandibular joints present congruent joint spaces with even subchondral bone surfaces and are considered within normal limits.

Spayed Female: Both tympanic bullae are aerated, the mucosal lining is not seen, the bony wall is smooth and thin. The external ear canals are within normal limits.

AGE: The brain presents no deviation from normal anatomy and symmetry. The brain parenchyma is homogeneous and within normal limits for attenuation and distribution of contrast enhancement. The ventricular system is non-dilated and symmetric.

INTERPRETED BY: The submandibular and medial retropharyngeal lymph nodes are small and elongated with a normal short-to-long-axis-ratio is < 0.5, the attenuation and contrast enhancement pattern is uniform.

Sebastian Schaub, DVM Dr. med. vet. DipECVDI
COMPUTED TOMOGRAPHIC DIAGNOSIS

- Structurally normal brain

HOSPITAL NAME: Bluegrass VS
INTERPRETATION OF THE FINDINGS & FURTHER RECOMMENDATIONS

REFERRING VET: In the present study of the brain there is no evidence of macromorphological disease, which supports the presumptive diagnosis of idiopathic epilepsy.

Gover: If not yet done so the workup should be complemented by examination of CSF and complete bloodwork to screen for brain disease that is not necessarily associated with structural changes of the brain parenchyma and rule out hepatoencephalopathy and other systemic illness. In case of the strong clinical suspicion of structural intraparenchymal changes an MRI may be considered.

INVOICE: 13894

DATE

10/20/21



PATIENT

Pippa West

SPECIES

Canine

BREED

Retriever Mix

SEX

Spayed Female

AGE

4.5 Years

INTERPRETED BY

Sebastian Schaub,
DVM Dr. med. vet.
DipECVDI

HOSPITAL NAME

Bluegrass VS

REFERRING VET

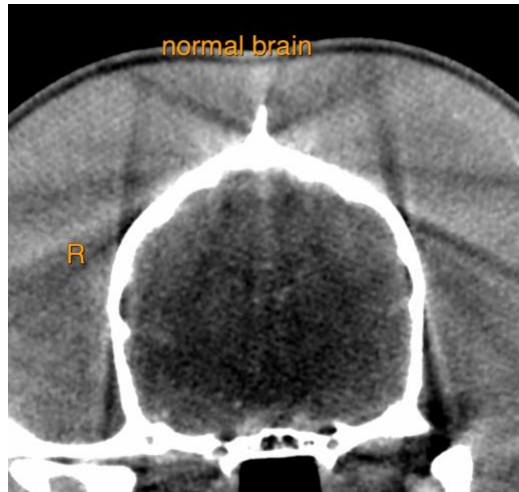
Gover

INVOICE

13894

DATE

10/20/21



The information and recommendations provided are based on the images presented by the referring veterinarian. No evaluation can be communicated regarding pathology that was not visible in the image/video clips provided.

Thank you for this referral. If the clinical or image interpretation does not parallel your findings or if I can be of any further assistance please contact me.

Sebastian Schaub, Sebastian Schaub, DVM, Dr. med. vet. DipECVDI
sebast.schaub@gmail.com