



**PATIENT PRESENTING CLINICAL SIGNS**

**Blue Edwards** History: 4-week history of primarily R-sided epistaxis, occasionally bilateral. Dispensed antibiotics for probable nasal tumor, no improvement since starting. 1 week history of suspected R-sided vestibular disease, initially noted nystagmus now resolved with ongoing head tilt.

**SPECIES**

**Canine** Abnormal PE/Chem/CBC/UA Results: Mucopurulent R-sided nasal discharge. R-sided head tilt. Otherwise WNL. CBC: lymphocytes=979 (1060-4950) /uL CHEMISTRY: WNL T4=1.3 (1.0-4.0) ug/dL Abdominal U/S: Geriatric abdomen. Minor, heterogenous splenic and hepatic changes.

**BREED COMPUTED TOMOGRAPHIC STUDY OF THE SKULL**

**Pit Bull Mix** A high resolution pre- and post-contrast CT study of the skull is provided for review.

**SEX COMPUTED TOMOGRAPHIC FINDINGS**

**Neutered Male** Triadan 109 is absent. Part of the crown of triadan 404 is absent and the stump of the crown presents irregular surface and advanced tooth root resorption. Triadan 110 presents mild to moderate periapical widening of the periodontal space.

**AGE**

**14 Years** The right nasal cavity presents extensive destruction of the conchal and turbinate structures with resulting 'empty nose'. Post contrast administration the nasal mucosal lining is moderately thickened and a moderate amount of non-contrast enhancing soft tissue material is attached to the mucosal surface. The right maxillary bone and osseous lining of the right frontal sinus present multiple regions with mild hyperostosis.

**INTERPRETED BY**

**Sebastian Schaub, DVM Dr. med. vet. DipECVDI** In the left nasal cavity, a mild amount of non-contrast enhancing soft tissue material is seen in the ventral aspect of the nasal cavity.

**HOSPITAL NAME**

**Healing Spirit AW** Both temporomandibular joints present congruent joint spaces with even subchondral bone surfaces and are considered within normal limits.

Both tympanic bullae are aerated, the mucosal lining is not seen, the bony wall is smooth and thin. The external ear canals are within normal limits.

**REFERRING VET**

**Desen Ertunc** The brain presents no deviation from normal anatomy and symmetry. The brain parenchyma is homogeneous and within normal limits for attenuation and distribution of contrast enhancement. The ventricular system is non-dilated and symmetric.

**INVOICE**

13915

**COMPUTED TOMOGRAPHIC DIAGNOSIS**

- Right sided destructive rhinitis with hyperostosis of the associated osseous structures

**DATE**

10/20/21



**PATIENT**

- Chronic complicated dental fracture 404 with advanced tooth root resorption
- Periapical granuloma 110

Blue Edwards

**INTERPRETATION OF THE FINDINGS & FURTHER RECOMMENDATIONS**

The findings are consistent with right sided mycotic destructive rhinitis. Although infectious agent Aspergillus is likely, Cryptococcus, Rhinosporidium or Blastomyces are potential differentials as well. There is no evidence of nasal neoplasia.

**SPECIES**

Canine

Recommended rhinoscopy for of the nasal cavities with sampling for culture and histopathology (detection of fungi microscopically is more straightforward than with culture in many cases). Local antimycotic therapy would be the therapy of choice.

**BREED**

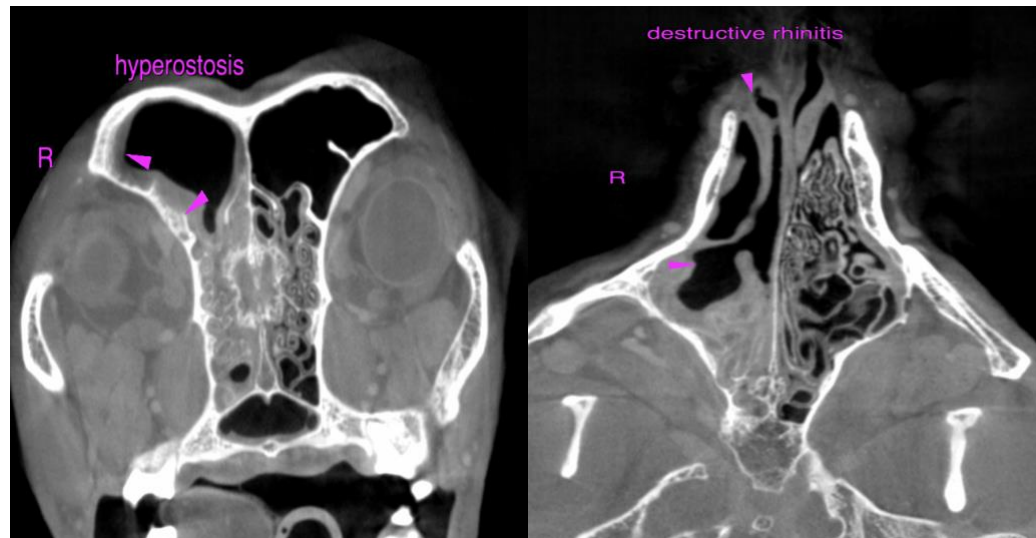
Pit Bull Mix

**SEX**

Neutered Male

**AGE**

14 Years



**INTERPRETED BY**

Sebastian Schaub, DVM Dr. med. vet. DipECVDI

**The information and recommendations provided are based on the images presented by the referring veterinarian. No evaluation can be communicated regarding pathology that was not visible in the image/video clips provided.**

**HOSPITAL NAME**

Healing Spirit AW

Thank you for this referral. If the clinical or image interpretation does not parallel your findings or if I can be of any further assistance please contact me.

**REFERRING VET**

Desen Ertunc

Sebastian Schaub, Sebastian Schaub, DVM, Dr. med. vet. DipECVDI  
sebast.schaub@gmail.com

**INVOICE**

13915

**DATE**

10/20/21



**PATIENT**

Blue Edwards

**SPECIES**

Canine

**BREED**

Pit Bull Mix

**SEX**

Neutered Male

**AGE**

14 Years

**INTERPRETED BY**

Sebastian Schaub,  
DVM Dr. med. vet.  
DipECVDI

**HOSPITAL NAME**

Healing Spirit AW

**REFERRING VET**

Desen Ertunc

**INVOICE**

13915

**DATE**

10/20/21