



PATIENT PRESENTING CLINICAL SIGNS

PATIENT Rocky Grant **PRESENTING CLINICAL SIGNS** History: Was coughing few months ago , gave Clavamox & Doxycycline , Got better then cough got worse again . Overweight, coughing a lot during the night .

SPECIES Abnormal PE/Chem/CBC/UA Results: HEMATOLOGY TEST RESULT REF.RANGE/UNITS RBC 7.3 5.4 - 8.7 x10E12/L Hematocrit 0.50 0.38 - 0.57 L/L Hemoglobin 172 134 - 207 g/L MCV 68.5 59.0 - 76.0 fL
Canie MCH 23.6 21.9 - 26.1 pg MCHC 344.0 326.0 - 392.0 g/L RDW 16.6 10.0 - 19.0 % Reticulocyte 1.5 %
 10.0 - 110.0 x10E3/uL Reticulocytes 109.5 Reticulocyte 24.5 - 31.8 pg Hemoglobin 24.6 WBC 9.7 4.9 - 17.6 x10E9/L % Neutrophils 73.2 % % Lymphocytes 13.4 % % Monocytes 9.0 % % Eosinophils 4.2 %
BREED % Basophils 0.2 % Neutrophils 7.1 2.9 - 12.7 x10E9/L Lymphocytes 1.3 1.1 - 5.0 x10E9/L Monocytes 0.9 0.0 - 1.2 x10E9/L Eosinophils 0.4 0.0 - 1.5 x10E9/L Basophils 0.0 0.0 - 0.1 x10E9/L Platelets 334 143 - 448 x10E9/L CBC Comment RBC, WBC, and platelet morphology normal CHEMISTRY TEST RESULT REF.RANGE/UNITS Glucose 6.2 3.5 - 6.3 mmol/L IDEXX SDMA a 8 0 - 14 ug/dL Creatinine 58 44 - 133 umol/L Urea (BUN) 7.4 3.2 - 11.0 mmol/L Phosphorus 1.5 0.8 - 2.0 mmol/L Calcium 2.6 2.2 - 2.8 mmol/L

SEX

Neutered Male

RADIOGRAPHIC STUDY OF THE THORAX

A complete set of radiographs of the thorax is provided for review. Radiographs are provided in JPEG file format.

AGE

9 Years

RADIOGRAPHIC FINDINGS

The body condition score is 9/9.

INTERPRETED BY

Sebastian Schaub,
 DVM Dr. med. vet.
 DipECVDI

Moderate spondylosis formation is present along the thoracic spine. Both elbow joints present evidence of osteophyte formation.

The heart is of normal size and shape, there is no evidence of cardiac chamber or vascular enlargement. The pulmonary vasculature is within normal limits.

HOSPITAL NAME

Wilson Road VC

The cranial mediastinum presents the expected soft tissue opacity. The mediastinal width is less than twice the width of the vertebral column at the same level.

REFERRING VET

Dr. Ehab Yessa

The trachea is normal in diameter and presents the anticipated course. The luminal outline of the trachea is smooth.

The bronchial tree presents with thin walls and tapers uniformly towards the periphery as expected. The lung parenchyma presents a generalized moderate increased radiopacity.

INVOICE

13490

The diaphragm is well delineated with even surface and the expected mild cranial bulging of the diaphragmatic cupola.

RADIOGRAPHIC DIAGNOSIS

DATE

10/2/21



PATIENT

Rocky Grant

- Obesity
- Degenerative osteoarthritis elbow joints
- Spondylosis deformans

INTERPRETATION OF THE FINDINGS & FURTHER RECOMMENDATIONS

SPECIES

Canine

The main finding is the obesity of the patient and the obesity is considered as the underlying cause for the generalized increased radiopacity of the lung parenchyma. No overt changes can be appreciated however given the clinical signs, underlying bronchitis is considered as the top differential- allergic/inflammatory non-infectious is considered likely. The cardiac silhouette is accentuated by pericardial and mediastinal fat, if a cardiac murmur is present a cardiac echo can be used for further assessment of cardiac chamber size and function.

BREED

Pug

Bronchoscopy including a BAL would be ideal for further workup.

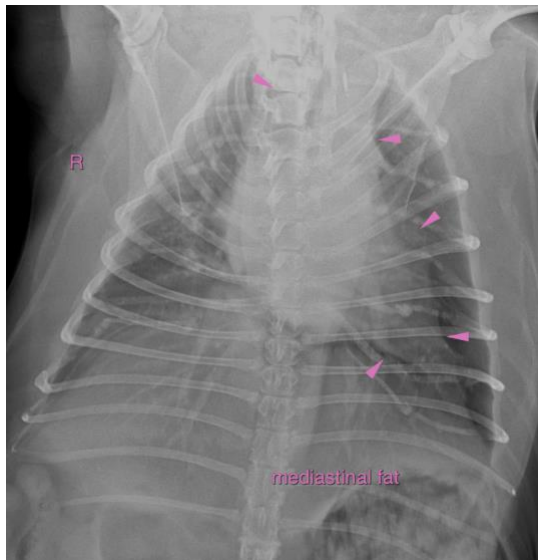
Weight management appears beneficial as well.

SEX

Neutered Male

AGE

9 Years



INTERPRETED BY

Sebastian Schaub,
DVM Dr. med. vet.
DipECVDI

HOSPITAL NAME

Wilson Road VC

The information and recommendations provided are based on the images presented by the referring veterinarian. No evaluation can be communicated regarding pathology that was not visible in the image/video clips provided.

REFERRING VET

Dr. Ehab Yessa

Thank you for this referral. If the clinical or image interpretation does not parallel your findings or if I can be of any further assistance please contact me.

INVOICE

13490

Sebastian Schaub, Sebastian Schaub, DVM, Dr. med. vet. DipECVDI
sebast.schaub@gmail.com

DATE

10/2/21



PATIENT

Rocky Grant

SPECIES

Canine

BREED

Pug

SEX

Neutered Male

AGE

9 Years

INTERPRETED BY

Sebastian Schaub,
DVM Dr. med. vet.
DipECVDI

HOSPITAL NAME

Wilson Road VC

REFERRING VET

Dr. Ehab Yessa

INVOICE

13490

DATE

10/2/21