



PATIENT

Pumpkin Valle

PRESENTING CLINICAL SIGNS

Losing weight and Grade 4 heart murmur

SPECIES

Feline

RADIOGRAPHIC STUDY OF THE THORAX

Radiographs of the thorax in three imaging planes are provided for review.

BREED

Domestic shorthair

RADIOGRAPHIC FINDINGS

Multifocal mild spondylosis formation is seen along the thoracic spine.

The extrathoracic soft tissues present homogeneous without abnormalities.

The cardiac silhouette is moderately rotated and presents a broad sternal contact. The cardiac silhouette is mildly prominent and elongated with a mild concave shape of the caudal border. The pulmonary vasculature is within normal limits.

SEX

Neutered Male

The trachea is normal in diameter and presents the anticipated course. The luminal outline of the trachea is smooth.

The bronchial tree presents with thin walls and tapers uniformly towards the periphery as expected.

AGE

12 Years

The lung parenchyma presents the expected architecture and opacity; the intrapulmonary vascular branching is seen up to the third order lung vessels.

INTERPRETED BY

Sebastian Schaub, DVM
Dr. med. vet. DipECVDI

The diaphragm is well delineated with even surface and the expected mild cranial bulging of the diaphragmatic cupola.

RADIOGRAPHIC DIAGNOSIS

- Mild cardiomegaly, no signs of decompensation
- Spondylosis deformans

HOSPITAL NAME

Truscott Animal
Hospital

INTERPRETATION OF THE FINDINGS & FURTHER RECOMMENDATIONS

The mild prominent cardiac silhouette can be a sequela to underlying cardiomyopathy – hypertrophic cardiomyopathy (HCM) would be most common. However, a cardiac echo is warranted to rule in/out underlying cardiomyopathy entirely. There are no signs of decompensation.

REFERRING VET

Dr. Medhat Meawad

In two lateral projections the diaphragm has a mild undulating shape – considered as dynamic finding of the diaphragm. Theoretically a hepatic mass might cause distortion of the diaphragm, but there are no signs for overt alteration of the shape of the liver.

INVOICE

54728

The remainder of the thoracic structures present no abnormalities.

DATE

10-19-22



PATIENT

Pumpkin Valle

SPECIES

Feline

BREED

Domestic shorthair

SEX

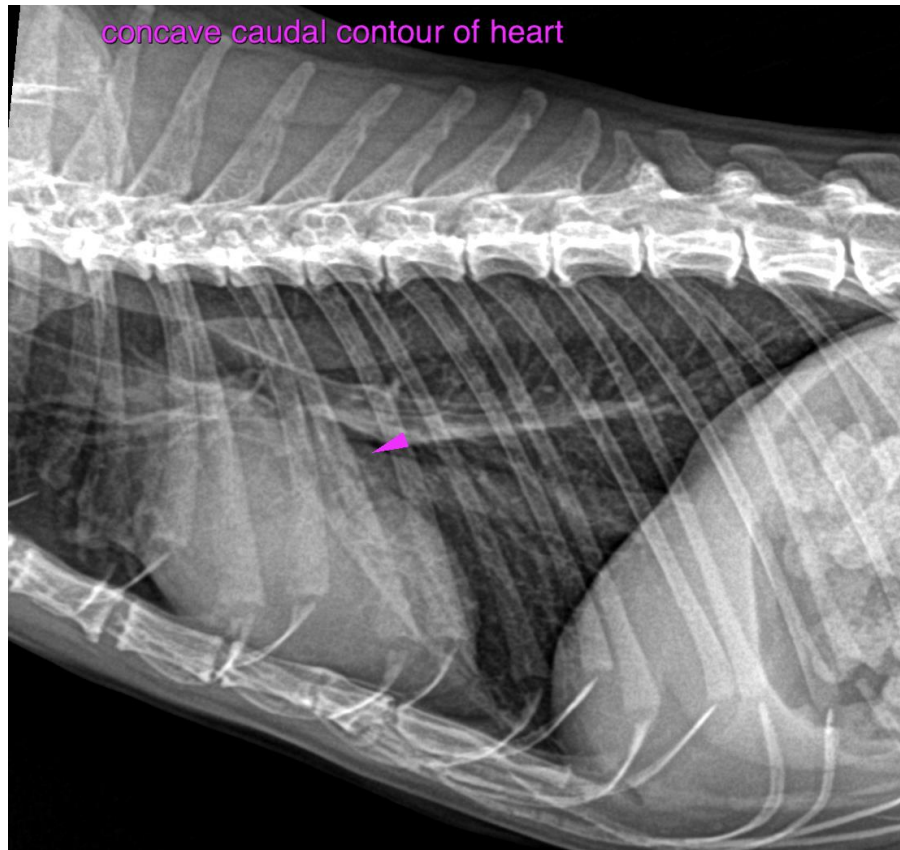
Neutered Male

AGE

12 Years

INTERPRETED BY

Sebastian Schaub, DVM
Dr. med. vet. DipECVDI



HOSPITAL NAME

Truscott Animal
Hospital

REFERRING VET

Dr. Medhat Meawad

INVOICE

54728

DATE

10-19-22

The information and recommendations provided are based on the images presented by the referring veterinarian/sonographer. No evaluation can be communicated regarding pathology that was not visible in the image/video clips provided.

Thank you for this referral. If the clinical or image interpretation does not parallel your findings or if I can be of any further assistance please contact me.

Sebastian Schaub, Sebastian Schaub, DVM, Dr. med. vet. DipECVDI
sebast.schaub@gmail.com