



PATIENT PRESENTING CLINICAL SIGNS

Nala Ngan 9 yo Shih Tzu; 5 day history of neck pain, reluctance to walk. exam: mild right lateralizing tetraparesis and proprioceptive ataxia; subtle right head tilt, left sided horner's syndrome.

SPECIES MAGNETIC RESONANCE IMAGING OF THE NECK

Canine T2 & T1 (DIXON) weighted pre- and post-gadolinium sequences in multiple imaging planes are provided for review.

BREED MAGNETIC RESONANCE IMAGING FINDINGS

Shih Tzu Level with the left neuroforamen C2/C3, a spadicaceous T2 and STIR heterogeneous strong hyperintense spadicaceous mass is protruding from the extraforaminal space into the vertebral canal; measuring 17 x 13 x 18 mm in size. The left neuroforamen C2/C3 is moderately widened by the mass effect. In the extraforaminal space the mass is splitting up in a dorsal and ventral branch. The spinal cord at the same level is displaced to the right, dorsally and distorted. The mass is merging with the ventral aspect of the spinal cord at the same level. Post contrast administration the spadicaceous mass is peripherally accentuated strong contrast enhancing.

SEX

FS

AGE

9 Years

MAGNETIC RESONANCE IMAGING DIAGNOSIS

- Tubular intra- and extradural mass with extraforaminal extend level with left neuroforamen C2/C3 with compressive myelopathy
- Pressure erosion left neuroforamen C2/C3

INTERPRETED BY

Sebastian Schaub, DVM
Dr. med. vet. DipECVDI

INTERPRETATION OF THE FINDINGS & FURTHER RECOMMENDATIONS

The tubular mass in the left neuroforamen C2/C3 with the intradural – possible intramedullary – extend is highly suggestive for segmental neuropathy of the left spinal nerve C3 and peripheral malignant nerve sheath tumor is the top differential. Primary soft tissue neoplasia is considered less likely, such as myxosarcoma, fibrosarcoma, lymphosarcoma. Ultrasound guided FNA sampling can be tried for further definition.

HOSPITAL NAME

Animal Health Partners

The finding is a plausible explanation for the presenting clinical signs.

REFERRING VET

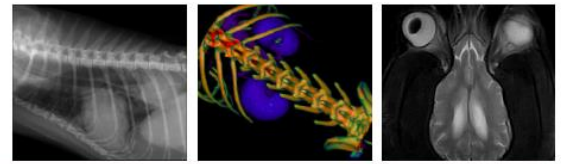
Dr. Stephanie Lovell

INVOICE

54729

DATE

10-19-22



PATIENT

Nala Ngan

SPECIES

Canine

BREED

Shih Tzu

SEX

FS

AGE

9 Years

INTERPRETED BY

Sebastian Schaub, DVM
Dr. med. vet. DipECVDI

HOSPITAL NAME

Animal Health
Partners

REFERRING VET

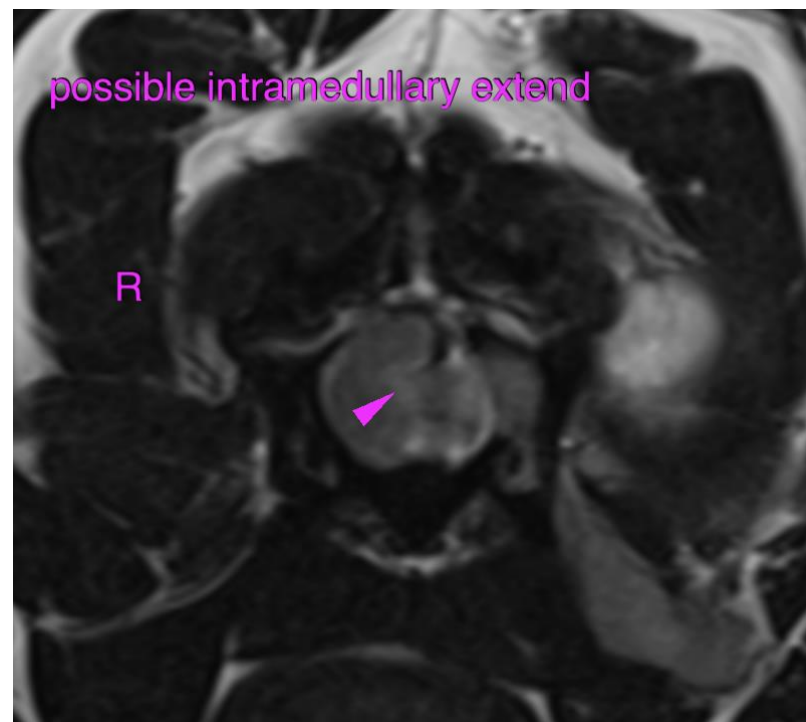
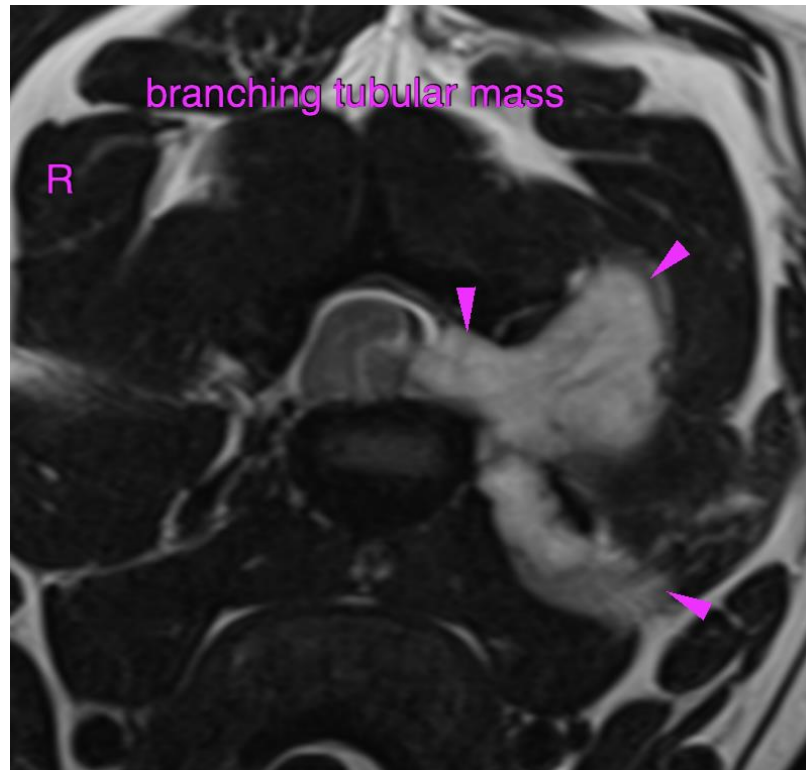
Dr. Stephanie Lovell

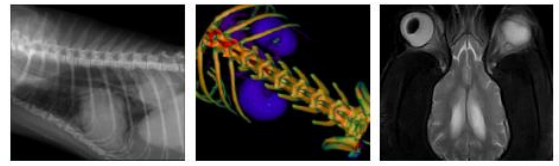
INVOICE

54729

DATE

10-19-22





PATIENT

Nala Ngan

SPECIES

Canine

The information and recommendations provided are based on the images presented by the referring veterinarian/sonographer. No evaluation can be communicated regarding pathology that was not visible in the image/video clips provided.

BREED

Shih Tzu

Thank you for this referral. If the clinical or image interpretation does not parallel your findings or if I can be of any further assistance please contact me.

Sebastian Schaub, Sebastian Schaub, DVM, Dr. med. vet. DipECVDI
sebast.schaub@gmail.com

SEX

FS

AGE

9 Years

INTERPRETED BY

Sebastian Schaub, DVM
Dr. med. vet. DipECVDI

HOSPITAL NAME

Animal Health
Partners

REFERRING VET

Dr. Stephanie Lovell

INVOICE

54729

DATE

10-19-22