



PATIENT

Ellie Murphy

PRESENTING CLINICAL SIGNS

presented for having a SQ mass on her chest that is connected to her inside L front leg. Previous masses reported to be lipomas removed.

SPECIES

Canine

COMPUTED TOMOGRAPHY OF THE FRONT LIMBS

A high resolution pre- and post-contrast CT study of front limbs is provided for review provided for review.

BREED

Labrador Mix

COMPUTED TOMOGRAPHIC FINDINGS

In the left axillary region, within the left pectoral muscle, a well-defined, uniform fat attenuating ovoidal shaped mass measuring 4.9 x 7.1 x 9.2 cm in size is appreciated; resulting in generalized swelling of the left pectoral musculature.

Both shoulder joints present smooth osseous margins, unremarkable.

SEX

FS

The lung parenchyma is aerated and presents the expected architecture with randomly distributed interspersed punctuate mineralization.

AGE

11 Years

The periarticular bones of the left elbow joint present mild osteophyte new bone formation. At the cranial aspect of the tip of the medial coronoid process of the left elbow joint, an isolated, triangular shaped mineral attenuating body is visible, measuring approximately 2 mm in size.

INTERPRETED BY

Sebastian Schaub, DVM
Dr. med. vet. DipECVDI

COMPUTED TOMOGRAPHIC DIAGNOSIS

- Intramuscular lipoma left pectoral muscle
- Mild degenerative osteoarthritis left elbow joint due to fragmented medial coronoid process (FCP)
- Pulmonary osteomas
- No evidence of pulmonary metastatic disease

HOSPITAL NAME

Critical Vet
Care/Suncoast
Veterinary

INTERPRETATION OF THE FINDINGS & FURTHER RECOMMENDATIONS

The mass appreciated at the left cranioventral thoracic wall is compatible with an intramuscular lipoma within the left pectoral musculature. The of the fat attenuating intramuscular mass are well-defined and I wouldn't consider it to be infiltrative; complete surgical excision of the lipoma is considered feasible.

REFERRING VET

Dr. Young

INVOICE

54727

DATE

10-19-22



PATIENT

Ellie Murphy

SPECIES

Canine

BREED

Labrador Mix

SEX

FS

AGE

11 Years

INTERPRETED BY

Sebastian Schaub, DVM
Dr. med. vet. DipECVDI

HOSPITAL NAME

Critical Vet
Care/Suncoast
Veterinary

REFERRING VET

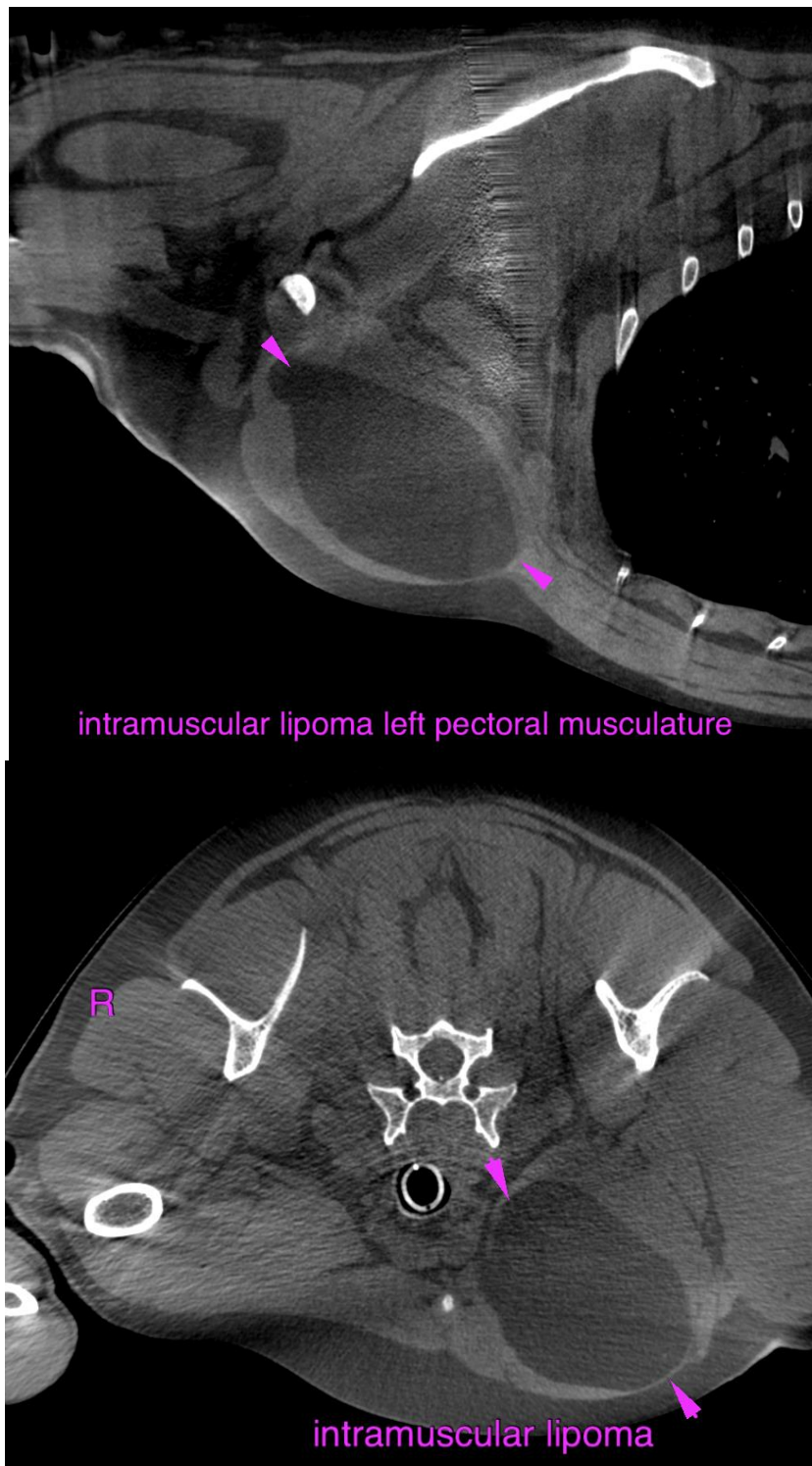
Dr. Young

INVOICE

54727

DATE

10-19-22





PATIENT

Ellie Murphy

SPECIES

Canine

BREED

Labrador Mix

SEX

FS

AGE

11 Years

INTERPRETED BY

Sebastian Schaub, DVM
Dr. med. vet. DipECVDI

HOSPITAL NAME

Critical Vet
Care/Suncoast
Veterinary

REFERRING VET

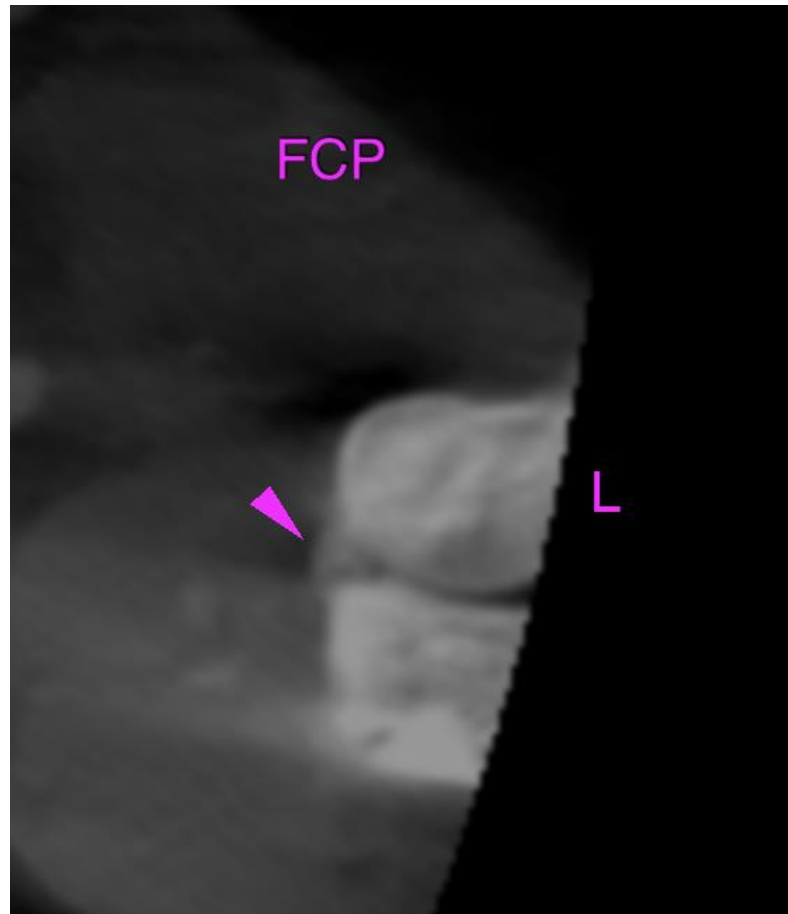
Dr. Young

INVOICE

54727

DATE

10-19-22



The information and recommendations provided are based on the images presented by the referring veterinarian/sonographer. No evaluation can be communicated regarding pathology that was not visible in the image/video clips provided.

Thank you for this referral. If the clinical or image interpretation does not parallel your findings or if I can be of any further assistance please contact me.

Sebastian Schaub, Sebastian Schaub, DVM, Dr. med. vet. DipECVDI
sebast.schaub@gmail.com