



PATIENT PRESENTING CLINICAL SIGNS

PATIENT Rocky Wigger
PRESENTING CLINICAL SIGNS History: 2 month history of right front lameness after play or sleeping. Grade 1/5 right front lameness, unable to localize source of pain.

SPECIES Abnormal PE/Chem/CBC/UA Results:

SPECIES Canine
RADIOGRAPHIC STUDY OF THE SHOULDER JOINTS

Radiographs of the shoulder joints in two imaging planes are provided for review.

BREED Rottweiler
RADIOGRAPHIC FINDINGS

Two ovoid shaped, small (<4mm) mineralized bodies are seen at the cranial aspect of the greater tubercle of the right humerus, level with the insertion of the supraspinatus muscle. The remainder of the osseous structures of the right shoulder joint present smooth osseous margins, unremarkable. No abnormalities of the surrounding soft tissue structures are appreciated.

SEX

Neutered Male

The left shoulder joint presents without abnormalities.

AGE **RADIOGRAPHIC DIAGNOSIS**

6 Years 2 Months

- Suspect mild calcifying tendinopathy right supraspinatus muscle.
- Normal left shoulder joint

INTERPRETED BY

Sebastian Schaub,
 DVM Dr. med. vet.
 DipECVDI

INTERPRETATION OF THE FINDINGS & FURTHER RECOMMENDATIONS

Commonly the calcifying tendinopathy of the supraspinatus muscle is an incidental finding and not associated with clinical signs. No additional abnormalities of the shoulder joints are appreciated. In case of strong clinical suspicion for pathology of the bicipital tendon or rotator cuff injury, ultrasound of the shoulder joint can be used as an advanced imaging modality. Rule out pathology of the distal aspects of the front limb as well.

HOSPITAL NAME

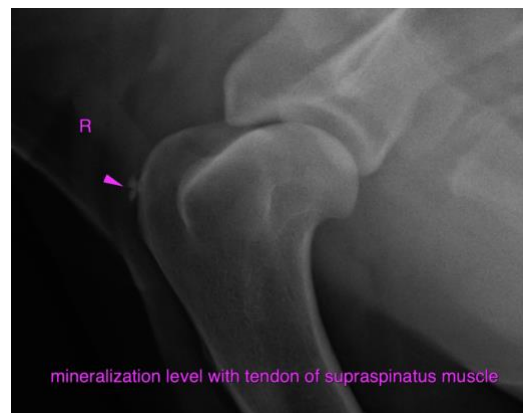
All Creatures AH of
 SH, Inc.

REFERRING VET

Dr. Jaquie Preston

INVOICE

13879



DATE

10/19/21



PATIENT

Rocky Wigger

The information and recommendations provided are based on the images presented by the referring veterinarian. No evaluation can be communicated regarding pathology that was not visible in the image/video clips provided.

SPECIES

Canine

Thank you for this referral. If the clinical or image interpretation does not parallel your findings or if I can be of any further assistance please contact me.

Sebastian Schaub, Sebastian Schaub, DVM, Dr. med. vet. DipECVDI
sebast.schaub@gmail.com

BREED

Rottweiler

SEX

Neutered Male

AGE

6 Years 2 Months

INTERPRETED BY

Sebastian Schaub,
DVM Dr. med. vet.
DipECVDI

HOSPITAL NAME

All Creatures AH of
SH, Inc.

REFERRING VET

Dr. Jaquie Preston

INVOICE

13879

DATE

10/19/21