



**PATIENT PRESENTING CLINICAL SIGNS**

Chubby Fiander History: went to VEC for being not himself, in pain , BW reveled elevated ALP

**SPECIES**

Canine

**RADIOGRAPHIC STUDY OF THE ABDOMEN**

Radiographs of the abdomen in three imaging planes are provided for review.

**BREED**

Shih Tzu

**RADIOGRAPHIC FINDINGS**

The surrounding bony structures are within normal limits.

**SEX**

Male

No abnormalities of the extraabdominal soft tissues are noted. The abdominal wall is smooth and thin.

The serosal detail is maintained throughout the peritoneal and retroperitoneal space.

**AGE**

12 Years

The liver is appropriate in position, size and presents uniform opacity.

The splenic head is in the anticipated position and within normal limits for size and opacity. The splenic body and tail are considered normal for position, size, shape and opacity.

**INTERPRETED BY**

Sebastian Schaub,  
DVM Dr. med. vet.  
DipECVDI

Both kidneys are seen and present with normal size, shape, delineation and opacity. The urinary bladder is in its anticipated position. No radiopaque calculi are noted throughout the upper and lower urinary tract. The prostate is moderately enlarged, measuring approximately 3.1 x 5.2 cm in size. The prostate has a uniform radiopacity.

The stomach is in its anticipated position and presents normal content.

**HOSPITAL NAME**

St. Catharine's AH

The small intestinal loops are of even diameter and non-dilated, a small amount of gas is seen within the small intestinal loops and considered within normal limits.

The colon is seen in the expected position and presents with appropriate content.

**REFERRING VET**

Dr. Masoud

**RADIOGRAPHIC DIAGNOSIS**

- Prostatomegaly

**INVOICE**

13890

**DATE**

10/19/21

**INTERPRETATION OF THE FINDINGS & FURTHER RECOMMENDATIONS**

The main finding of the current radiographic study of the abdomen is the enlarged prostate and the top differential in the intact male patient is benign prostatic hyperplasia. As prostatic neoplastic transformation – such as carcinoma – cannot be ruled out entirely, correlate this finding with palpatory



**PATIENT**

findings in the rectal examination. Ultrasound guided FNA sampling can be performed as an advanced diagnostic test, if applicable.

Chubby Fiander

**SPECIES**

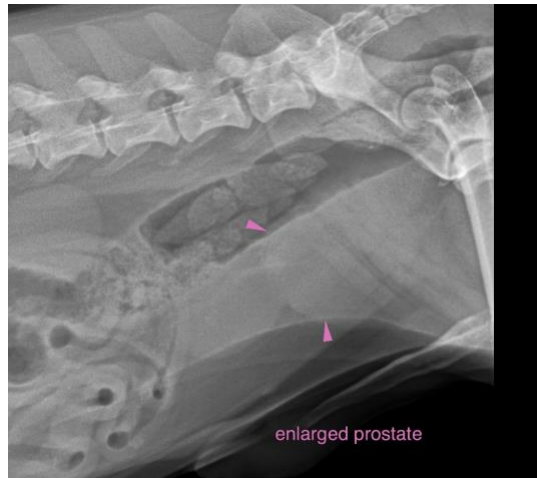
Canine

**BREED**

Shih Tzu

**SEX**

Male



**AGE**

12 Years

**The information and recommendations provided are based on the images presented by the referring veterinarian. No evaluation can be communicated regarding pathology that was not visible in the image/video clips provided.**

Thank you for this referral. If the clinical or image interpretation does not parallel your findings or if I can be of any further assistance please contact me.

**INTERPRETED BY**

Sebastian Schaub,  
DVM Dr. med. vet.  
DipECVDI

Sebastian Schaub, Sebastian Schaub, DVM, Dr. med. vet. DipECVDI  
sebast.schaub@gmail.com

**HOSPITAL NAME**

St. Catharine's AH

**REFERRING VET**

Dr. Masoud

**INVOICE**

13890

**DATE**

10/19/21