



PATIENT PRESENTING CLINICAL SIGNS

Ziggy Row
 A few days ago, owners' mother gave Ziggy some fish (which he normally doesn't have). After a nap she heard him vomit and then heard him fall over. She went to him and found a very large vomit pile with all of the food and him laying on his side. (A few seconds between her hearing the thump and her reaching her cat). He never lost consciousness but seemed groggy. O took him to an emergency vet where they did BW and an ECG and relayed that everything was unremarkable. Here for a recheck. O has confirmed that she has not heard him cough frequently (reports maybe 1-2 in a year) and doesn't seem to have any difficulty keeping up when playing. She has noticed that his hind legs seem to sometimes fall from under him and is extremely concerned that he could develop a saddle thrombus.

SPECIES

Feline

BREED

DSH

Abnormal PE/Chem/CBC/UA Results: BW done at emerge on October 14th show mild increases in BUN and ALT. CBC is unremarkable. BW repeated today (Oct 18th) show that those values have normalized. Everything else is unremarkable. No CBC run today.

SEX

NM

RADIOGRAPHIC STUDY OF THE THORAX

Radiographs of the thorax in three imaging planes are provided for review.

RADIOGRAPHIC FINDINGS

AGE

10 Years

The surrounding bony structures are within normal limits.

The extrathoracic soft tissues present homogeneous without abnormalities.

INTERPRETED BY

Sebastian Schaub, DVM
 Dr. med. vet. DipECVDI

The heart is of normal size and shape, there is no evidence of cardiac chamber or vascular enlargement. The pulmonary vasculature is within normal limits.

The trachea is normal in diameter and presents the anticipated course. The luminal outline of the trachea is smooth.

HOSPITAL NAME

Balmy Beach Pet
 Hospital

Generalized moderate peribronchial cuffing is present.

The lung parenchyma presents the expected architecture; the intrapulmonary vascular branching is seen up to the third order lung vessels.

REFERRING VET

Dr. Yogo

The diaphragm is well delineated with even surface and the expected mild cranial bulging of the diaphragmatic cupola.

RADIOGRAPHIC DIAGNOSIS

INVOICE

47832

- Bronchial lung pattern without evidence of air-trapping.

INTERPRETATION OF THE FINDINGS & FURTHER RECOMMENDATIONS

The pulmonary changes seen are suggestive for feline inflammatory lower airway disease, that may be subclinical due to the lack of clinical signs.

DATE

10-18-21

The cardiovascular structures present no abnormalities. To rule out cardiac chamber enlargement completely, a cardiac echo can be used as advanced imaging modality.



PATIENT

Ziggy Row

SPECIES

Feline

BREED

DSH

SEX

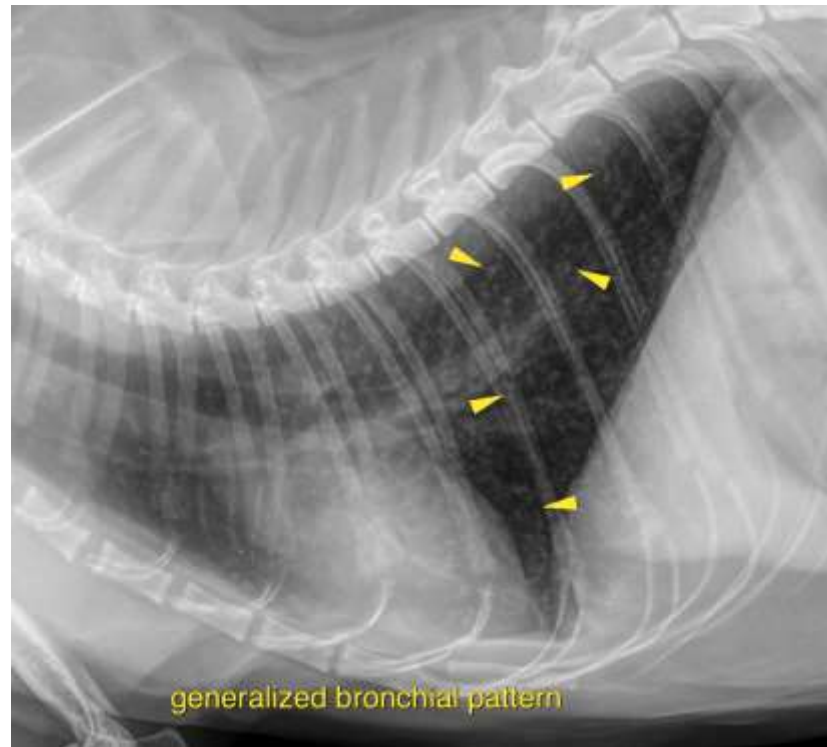
NM

AGE

10 Years

INTERPRETED BY

Sebastian Schaub, DVM
Dr. med. vet. DipECVDI



HOSPITAL NAME

Balmy Beach Pet
Hospital

REFERRING VET

Dr. Yogo

INVOICE

47832

DATE

10-18-21

The information and recommendations provided are based on the images presented by the referring veterinarian. No evaluation can be communicated regarding pathology that was not visible in the image/video clips provided.

Thank you for this referral. If the clinical or image interpretation does not parallel your findings or if I can be of any further assistance please contact me.

Sebastian Schaub, Sebastian Schaub, DVM, Dr. med. vet. DipECVDI
sebast.schaub@gmail.com