

PATIENT PRESENTING CLINICAL SIGNS

Maverick Krassner
 Dyspneic, Weight Loss, Anemic, Lat. chest x-ray- possible lung nodules; ABD x-ray- enlarged liver
 Current Meds: started on Amoxi 1000mg BID; Doxy 200mg BID
 Abnormal PE/Chem/CBC/UA Results: CBC Leukocytosis 75,000, Monocytosis & Neutrophilia;
 Chemistry-Pending

SPECIES

Canine

RADIOGRAPHIC STUDY OF THE THORAX & ABDOMEN

A right lateral projection of the thorax and the abdomen is provided for review.

BREED

Rottie/Lab

RADIOGRAPHIC FINDINGS

Thorax

The surrounding bony structures are within normal limits.

SEX

Male

The extrathoracic soft tissues present homogeneous without abnormalities.

The heart is of normal size and shape, there is no evidence of cardiac chamber or vascular enlargement. The trachea is normal in diameter and presents the anticipated course. The luminal outline of the trachea is smooth.

AGE

6 Years

The lung parenchyma presents a generalized significant, mild patchy, ground glass opacity, effacing the pulmonary vasculature.

INTERPRETED BY

Sebastian Schaub,
 DVM Dr. med. vet.
 DipECVDI

The diaphragm is well delineated with even surface and the expected mild cranial bulging of the diaphragmatic cupola.

Abdomen

The vertebral endplates L4/L5 present moderate spondylosis formation

HOSPITAL NAME

Byram AH

Very mild soft tissue striation of the peritoneal fat is noted.

The serosal detail is maintained throughout the peritoneal and retroperitoneal space. A roundish ill-defined soft tissue opacity is superimposed on the mid abdomen, measuring approximately 7 cm in size.

REFERRING VET

Dr. Maria Cruz

The hepatic volume is moderately increased and the liver is protruding caudally beyond the costal arch. The caudoventral hepatic margins are rounded.

The splenic body and tail are considered normal for position, size, shape and opacity.

INVOICE

42373

Both kidneys are seen and present with normal size, shape, delineation and opacity. The urinary bladder is in its anticipated position. No radiopaque calculi are noted throughout the upper and lower urinary tract.

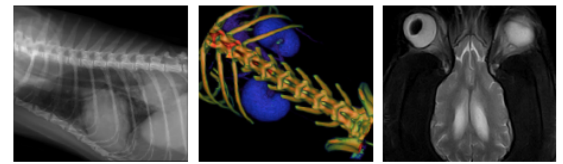
The stomach is in its anticipated position and presents normal content.

DATE

10/26/22

RADIOGRAPHIC DIAGNOSIS

- Generalized unstructured interstitial lung pattern



PATIENT
Maverick Krassner

- Suspect mid abdominal soft tissue mass
- Hepatomegaly
- Suspect mild peritoneal effusion
- Spondylosis deformans

SPECIES **INTERPRETATION OF THE FINDINGS & FURTHER RECOMMENDATIONS**

Canine
The unstructured interstitial lung pattern is not specific and differentials would include fibrosis, pneumonitis (inflammatory versus infectious), systemic disease (e.g. pancreatitis, IMHA, renal disease), neoplasia (e.g. lymphosarcoma, carcinomatosis).

BREED
Rottie/Lab
The impression of a mid abdominal mass can be caused by odd superimposition of the left kidney, however a 'real' mid abdominal mass such as lymphadenopathy, mass of the splenic head, cyst, granuloma or less likely abscess are considerations.

SEX
Male
Potentials for the hepatomegaly include metabolic hepatic disease/steroid induced hepatopathy, hepatitis or neoplastic infiltration. Ultrasound including FNA sampling can be used as minimally advanced diagnostic tests.

AGE
6 Years
Complementing workup at least by a second imaging plane of the abdomen or ideally by an abdominal ultrasound examination including FNA sampling would be ideal. If the abdominal mass can be confirmed, the odds for underlying disseminated neoplastic disease are considered high. Check for possible infectious disease such as Babesiosis, Ehrlichiosis, Leptospirosis, etc.

INTERPRETED BY

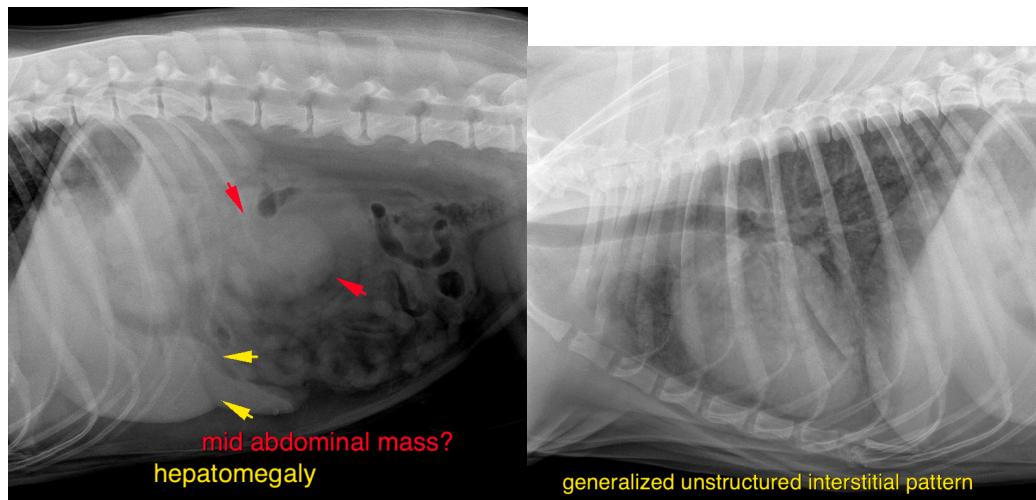
Sebastian Schaub,
DVM Dr. med. vet.
DipECVDI

HOSPITAL NAME

Byram AH

REFERRING VET

Dr. Maria Cruz



INVOICE

42373

DATE

10/26/22

The information and recommendations provided are based on the images presented by the referring veterinarian. No evaluation can be communicated regarding pathology that was not visible in the image/video clips provided.

Thank you for this referral. If the clinical or image interpretation does not parallel your findings or if I can be of any further assistance please contact me.

Sebastian Schaub, Sebastian Schaub, DVM, Dr. med. vet. DipECVDI
sebast.schaub@gmail.com