



#### PATIENT

Tara Getty

#### PRESENTING CLINICAL SIGNS

History: Tara was presented for an intermittent thoracic limb lameness after exercise. P able to warm out of the injury.

#### SPECIES

Canine

Abnormal PE/Chem/CBC/UA Results: No lameness noted during physical exam. Full range of motion noted along all joints within the right and left thoracic limbs. No crepitus or pain elicited.

#### BREED

Akita

#### RADIOGRAPHIC STUDY OF THE SHOULDER & ELBOW JOINTS

A complete set of radiographs of the shoulder and elbow joints is provided for review.

#### RADIOGRAPHIC FINDINGS

Both shoulder joints presents smooth osseous margins, the surrounding soft tissue structures are within normal limits.

#### SEX

Spayed Female

The subchondral bone of the elbow joints has smooth margins. The contour of the medial coronoid process of the elbow joints presents a homogeneous density and well-defined sharp margins.

#### AGE

7 Years 8 Months

#### RADIOGRAPHIC DIAGNOSIS

- Normal shoulder joints
- Normal elbow joints

#### INTERPRETATION OF THE FINDINGS & FURTHER RECOMMENDATIONS

#### INTERPRETED BY

Sebastian Schaub,  
DVM Dr. med. vet.  
DipECVDI

The radiographic study of the shoulder and elbow joints presents without abnormalities. In case of strong clinical suspicion for pathology of the bicipital tendon or rotator cuff injury an ultrasound examination of the shoulder joints can be used as an advanced imaging modality. If the patient is painful when testing the medial coronoid process, consider CT study of the elbow joints.

#### HOSPITAL NAME

DTLAvets

**The information and recommendations provided are based on the images presented by the referring veterinarian. No evaluation can be communicated regarding pathology that was not visible in the image/video clips provided.**

Thank you for this referral. If the clinical or image interpretation does not parallel your findings or if I can be of any further assistance please contact me.

#### REFERRING VET

Dr. Endo

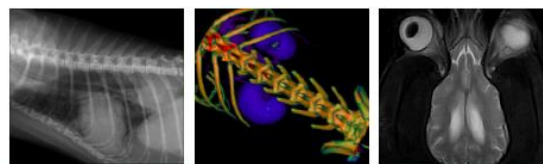
**Sebastian Schaub**, Sebastian Schaub, DVM, Dr. med. vet. DipECVDI  
sebast.schaub@gmail.com

#### INVOICE

13825

#### DATE

10/16/21



**PATIENT**

Tara Getty

**SPECIES**

Canine

**BREED**

Akita

**SEX**

Spayed Female

**AGE**

7 Years 8 Months

**INTERPRETED BY**

Sebastian Schaub,  
DVM Dr. med. vet.  
DipECVDI

**HOSPITAL NAME**

DTLAvets

**REFERRING VET**

Dr. Endo

**INVOICE**

13825

**DATE**

10/16/21