



PATIENT PRESENTING CLINICAL SIGNS

Zori Bluma Pt begin having bowl movement accidents about 3 weeks ago. Begin to urinate in the house about 2 days ago. Today pt started crying in pain when playing with housemates. Ambulatory x4, painful on hip extension and worst on right front shoulder extension. Painful on thoracic and thoracolumbar palpation, normal range of neck.

SPECIES

Canine

COMPUTED TOMOGRAPHY OF THE THORAX AND ABDOMEN

A high resolution pre- and post-contrast CT study of the abdomen and a post-contrast CT study of the thorax are provided for review.

BREED

Chihuahua Mix

COMPUTED TOMOGRAPHIC FINDINGS

The body condition score is 8/9.

SEX

SF

Thorax

Multiple intervertebral discs of the thoracic & lumbar spine present central mineralization. The vertebral endplates T12/T13 present moderate spondylosis formation. In the right neuroforamen T12/T13, irregular mineral attenuating disc material is visible, occupying approximately 80% of the cross-sectional area of the right neuroforamen T12/T13.

AGE

7 Years

The sternal, cranial mediastinal and tracheobronchial lymph nodes are small elongated with a normal short-to-long-axis-ratio is < 0.5, the attenuation and contrast enhancement pattern is uniform and considered within normal limits.

INTERPRETED BY

Sebastian Schaub, DVM
Dr. med. vet. DipECVDI

The cardiovascular structures including the pulmonary vasculature are within normal limits.

The bronchial tree presents with regular branching and tapers uniformly towards the periphery as expected, the bronchial walls are thin and smooth. The bronchus-to-artery ratio is within normal limits.

HOSPITAL NAME

Scottsdale Veterinary
Clinic

The caudodorsal dependent aspects of the lung lobes bilaterally and the left lung lobes present multiple regions with compression atelectasis of the lung parenchyma. The remainder of the lung parenchyma present the expected architecture and attenuation behavior.

Small incidental gas pockets are seen within the esophageal lumen, there is no evidence of abnormal dilation.

REFERRING VET

Dr. Hertz

Abdomen

The serosal fat presents normal attenuation behavior. There is no evidence of peritoneal effusion or peritonitis.

INVOICE

54633

Both kidneys present within normal limits for size, shape and organ architecture. After contrast administration a bilaterally symmetric and uniform nephro- and pyelogram is noted.

The adrenal glands are within normal limits for size, shape and organ architecture.

DATE

10-15-22

Both liver and spleen present with normal shape, even surface, uniformly attenuating parenchyma and homogeneous contrast enhancement, unremarkable.

The caudate process of the right caudal lung lobe and the left medial liver lobe present with small (<6 mm) roundish parenchymal filling defects.

The pancreas is evenly contoured, the pancreatic parenchyma is homogeneous and presents



PATIENT uniform contrast enhancement.

Zori Bluma The position, delineation, wall and content of the gastrointestinal tract are considered within normal limits throughout.

SPECIES The bony and surrounding soft tissue structures reveal no abnormalities.

Canine

BREED

Chihuahua Mix

COMPUTED TOMOGRAPHIC DIAGNOSIS

- Hepatic cysts
- Right sided foraminal intervertebral disc protrusion T12/T13
- Compression atelectasis, predominantly left lung lobes due to general anesthesia
- Multifocal chondroid disc degeneration
- Spondylosis deformans T12/T13

INTERPRETATION OF THE FINDINGS & FURTHER RECOMMENDATIONS

SEX The foramina intervertebral disc extrusion T12/T13 can be a cause for pain, due to impingement of the right spinal nerve T12. There is lateral spondylosis formation at the same level, protruding into the region of the external opening of the right neuroforamen T12/T13 as well. If pain can be localized to the respective neuro-anatomical region and clinical signs are refractory to conservative the chances of surgical management can be discussed with neurologist.

SF

AGE

7 Years

No additional clinically relevant abnormalities of the thorax and abdomen are appreciated.

INTERPRETED BY

Sebastian Schaub, DVM
Dr. med. vet. DipECVDI

HOSPITAL NAME

Scottsdale Veterinary
Clinic

REFERRING VET

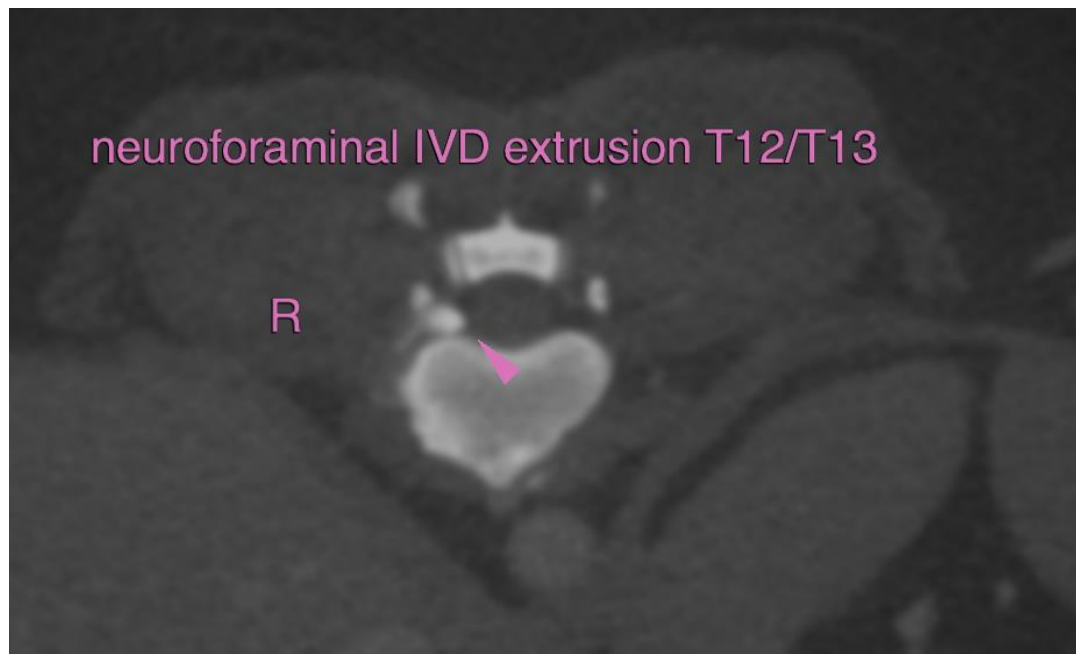Dr. Hertz

INVOICE

54633

DATE

10-15-22





PATIENT

Zori Bluma

SPECIES

Canine

BREED

Chihuahua Mix

SEX

SF

AGE

7 Years

INTERPRETED BY

Sebastian Schaub, DVM
Dr. med. vet. DipECVDI

HOSPITAL NAME

Scottsdale Veterinary
Clinic

REFERRING VET

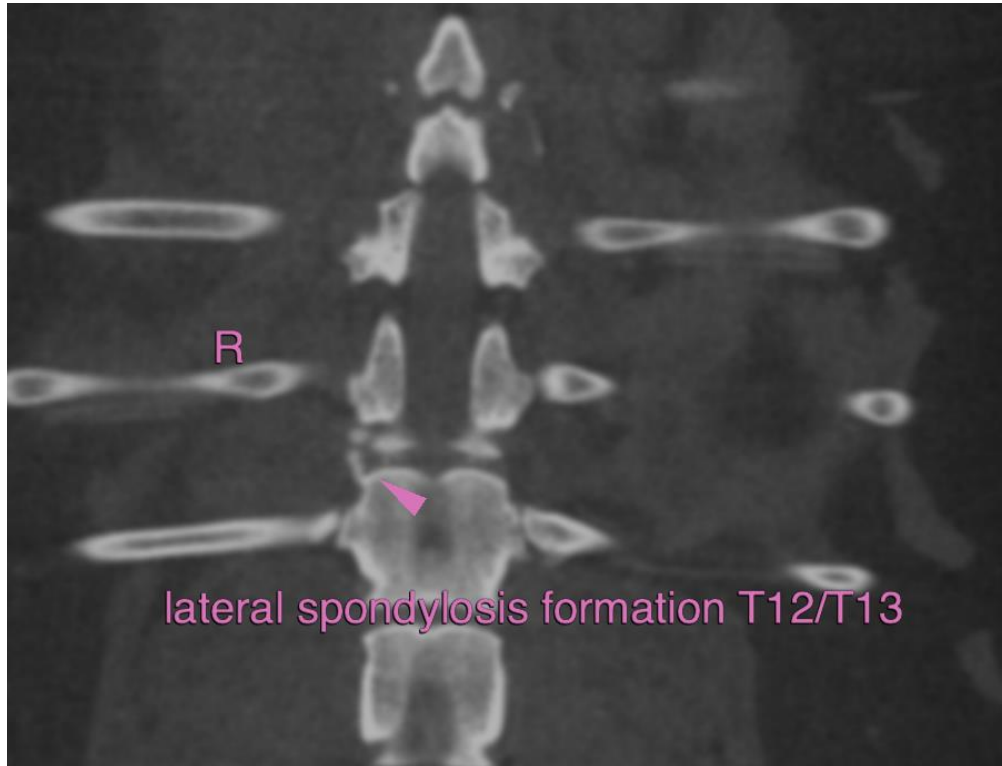
Dr. Hertz

INVOICE

54633

DATE

10-15-22



The information and recommendations provided are based on the images presented by the referring veterinarian/sonographer. No evaluation can be communicated regarding pathology that was not visible in the image/video clips provided.

Thank you for this referral. If the clinical or image interpretation does not parallel your findings or if I can be of any further assistance please contact me.

Sebastian Schaub, Sebastian Schaub, DVM, Dr. med. vet. DipECVDI
sebast.schaub@gmail.com