



PATIENT PRESENTING CLINICAL SIGNS

Winston Komer-Long History: Sudden onset of vomiting and diarrhea

SPECIES

Abnormal PE/Chem/CBC/UA Results: Mild Hyperglycemia and elevated ALT, and neutrophilia normal bloodwork otherwise fpl

Feline

RADIOGRAPHIC STUDY OF THE ABDOMEN

Radiographs of the abdomen in three imaging planes are provided for review.

BREED

Highland Lynx

RADIOGRAPHIC FINDINGS

The acetabular groove bilaterally is shallow and the center of the femoral heads is lateral to the dorsal acetabular rim.

SEX

Neutered Male

No abnormalities of the extraabdominal soft tissues are noted. The abdominal wall is smooth and thin. The serosal detail is maintained throughout the peritoneal and retroperitoneal space.

AGE

12 Months

The liver is appropriate in position, size and presents uniform opacity.

The splenic head is in the anticipated position and within normal limits for size and opacity.

INTERPRETED BY

Sebastian Schaub,
DVM Dr. med. vet.
DipECVDI

Both kidneys are seen and present with normal size, shape, delineation and opacity. The urinary bladder is in its anticipated position. No radiopaque calculi are noted throughout the upper and lower urinary tract.

The stomach is in its anticipated position and contains a mild amount of gas.

HOSPITAL NAME

St. Catharine's AH

The small intestinal loops are of even diameter and generalized mildly distended by gas.

The colon is seen in the expected position and is empty but moderate amount of gas.

RADIOGRAPHIC DIAGNOSIS

REFERRING VET

Dr. Masoud

- Gas pattern gastrointestinal tract
- Bilateral hip dysplasia

INTERPRETATION OF THE FINDINGS & FURTHER RECOMMENDATIONS

INVOICE

13817

There is no evidence of radiopaque foreign material or signs for gastrointestinal mechanical obstruction. The presumptive diagnosis is gastroenteritis. Recommend empirical management; if clinical signs are refractory to therapy either follow up radiographs or a complete abdominal ultrasound examination are recommended.

DATE

10/15/21



PATIENT

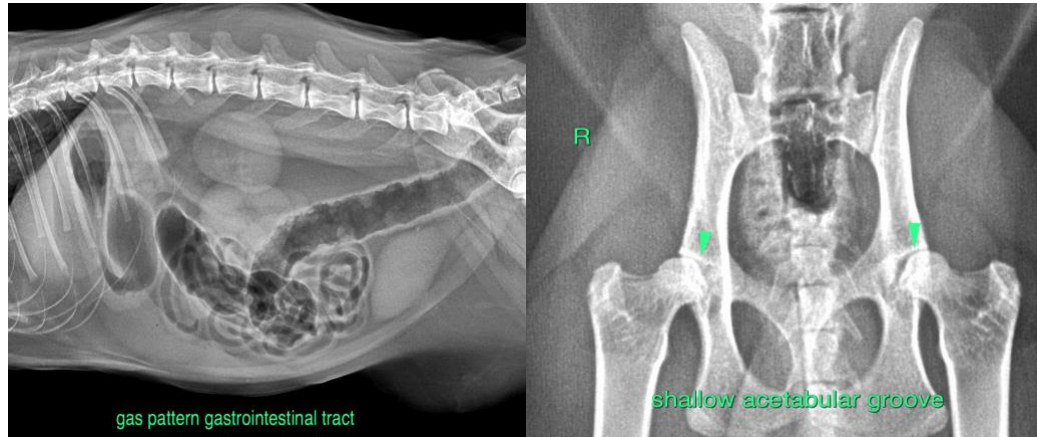
Winston Komer-Long

SPECIES

Feline

BREED

Highland Lynx



SEX

Neutered Male

The information and recommendations provided are based on the images presented by the referring veterinarian. No evaluation can be communicated regarding pathology that was not visible in the image/video clips provided.

AGE

12 Months

Thank you for this referral. If the clinical or image interpretation does not parallel your findings or if I can be of any further assistance please contact me.

Sebastian Schaub, Sebastian Schaub, DVM, Dr. med. vet. DipECVDI
sebast.schaub@gmail.com

INTERPRETED BY

Sebastian Schaub,
DVM Dr. med. vet.
DipECVDI

HOSPITAL NAME

St. Catharine's AH

REFERRING VET

Dr. Masoud

INVOICE

13817

DATE

10/15/21