



PATIENT PRESENTING CLINICAL SIGNS

Gizmo Williams History: BITE WOUNDS History: APPROX 3 1/2 YR OLD NEUTERED POODLE PRESENTED FOR MULTIPLE BITE WOUNDS FROM HOUSEMATE. YESTERDAY PET WAS BIT ON THE RIGHT REAR LEG INSIDE AND OUTSIDE. TODAY ALSO NOTED SOME DRIED BLOOD ON THE RIGHT SIDE NECK. PET IS PAINFUL IN THE BACK NOT WANTING TO WALK.

SPECIES

Canine Abnormal PE/Chem/CBC/UA Results: Hydration: N Mentation: N EENT: N Oral Cavity: N Lymph Nodes: N Skin: Puncture wound right distal lateral thigh. Moderate bruising right lateral/caudal thigh, both inner thighs and groin. 2cm scabbed over wound right dorsolateral neck. Removing the scab and matted adjacent hair reveals a deep pocket that extends over to left side of neck. CV/Respiratory: N
BREED Abd/GI: N Uro/Perineum: N Musculoskeletal: non-weight bearing to weight bearing lame right rear leg. Very painful on palpation and manipulation of right rear Swollen from right thigh down to hock
Poodle Neurological: N

SEX RADIOGRAPHIC STUDY OF THE PELVIS AND STIFLE JOINTS

Neutered Male A VD view of the pelvis and craniocaudal and mediolateral projection of the stifle joints is provided for review.

AGE RADIOGRAPHIC FINDINGS

3 Years 8 Months The osseous and surrounding soft tissue structures of the pelvis – including the coxofemoral joints – are within normal limits.

INTERPRETED BY

The osseous structures of the stifle joints are within normal limits.

Sebastian Schaub,
DVM Dr. med. vet.
DipECVDI

A moderate soft tissue swelling is seen at the caudal aspect of the gastrocnemius muscle of the hind limb that is in a caudal position in the lateral view.

HOSPITAL NAME RADIOGRAPHIC DIAGNOSIS

- DPC Veterinary H**
- Soft tissue swelling caudal aspect one hind limb
 - Normal pelvis

REFERRING VET INTERPRETATION OF THE FINDINGS & FURTHER RECOMMENDATIONS

Dr. Feldt The soft tissue swelling with the given history is suggestive for hematoma formation or steatitis due to bite wound. The osseous structures are within normal limits.

INVOICE

13811

DATE

10/15/21



PATIENT

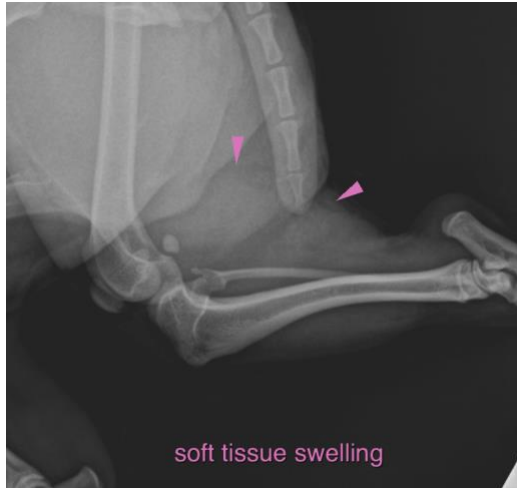
Gizmo Williams

SPECIES

Canine

BREED

Poodle



SEX

Neutered Male

The information and recommendations provided are based on the images presented by the referring veterinarian. No evaluation can be communicated regarding pathology that was not visible in the image/video clips provided.

AGE

3 Years 8 Months

Thank you for this referral. If the clinical or image interpretation does not parallel your findings or if I can be of any further assistance please contact me.

Sebastian Schaub, Sebastian Schaub, DVM, Dr. med. vet. DipECVDI
sebast.schaub@gmail.com

INTERPRETED BY

Sebastian Schaub,
DVM Dr. med. vet.
DipECVDI

HOSPITAL NAME

DPC Veterinary H

REFERRING VET

Dr. Feldt

INVOICE

13811

DATE

10/15/21