



PATIENT PRESENTING CLINICAL SIGNS

Claire Trotta History: Hx of lymphoma; recent hx of collapse; Hx of cushing's Dz (holistic tx by owner)
Abnormal PE/Chem/CBC/UA Results: Leukocytosis

SPECIES COMPUTED TOMOGRAPHIC STUDY OF THE SKULL

Canine A high resolution pre- and post-contrast CT study of the skull is provided for review.

COMPUTED TOMOGRAPHIC FINDINGS

BREED

Beagle Mix There is evidence of generalized periodontal diseases with ankylosis of the thooth roots. The distal root of triadan 108 presents a moderate widening of the periodontal space with perforation of the alveolar crest laterally. Generalized abrasion of the crowns of all roots is visible.

SEX

Spayed Female The nasal cavity presents the expected aerated spaces between thin and even conchae and turbinates with smooth mucosal lining.

AGE

15 Years Both temporomandibular joints present congruent joint spaces with even subchondral bone surfaces and are considered within normal limits.
Both tympanic bullae are aerated, the mucosal lining is not seen, the bony wall is smooth and thin. The external ear canals are within normal limits.

INTERPRETED BY

Sebastian Schaub, DVM Dr. med. vet. DipECVDI The brain presents no deviation from normal anatomy and symmetry. The brain parenchyma is homogeneous and within normal limits for attenuation and distribution of contrast enhancement. The ventricular system is non-dilated and symmetric. The pituitary gland is protruding dorsally beyond the level of the sella turcica; measuring 5 x 5 x 5 mm in size.

HOSPITAL NAME

Andover AH Generalized moderate to marked enlargement of the parotid, mandibular, medial retropharyngeal, superficial cervical, cranial mediastinal lymph nodes and left axillary lymph nodes is visible; the lymph nodes are rounded, uniform soft tissue attenuating and heterogeneous mild contrast enhancing. The surrounding fat presents mild fat-stranding.

REFERRING VET

Dr. Shelley Parker Originating from the left thyroid gland, a well-deifned, ovoid shaped, mild heterogeneous hyperattenuating and heterogeneous marked contrast enhancing mass is visible measuring 2.2 x 2.1 x 4.8 cm in size. Multiple small tortuous feeding vessels are seen in the periphery of the mass.
Multifocal moderate spondylosis formation is noted along the cervical spine. The intervertebral disc C3/C4 is mildly protruding into the vertebral canal, distorting the ventral epidural space.

INVOICE

13791

COMPUTED TOMOGRAPHIC DIAGNOSIS

- Generalized lymphadenomegaly of the lymph nodes of the skull and pictured parts of the thorax with mild surrounding steatitis

DATE

10/15/21



PATIENT

Claire Trotta

- Left thyroid mass
- Pituitary enlargement.
- Intervertebral disc protrusion C3/C4
- Generalized periodontal disease with dental abscess formation triadan 108
- Spondylosis deformans cervical spine

SPECIES

Canine

INTERPRETATION OF THE FINDINGS & FURTHER RECOMMENDATIONS

BREED

Beagle Mix

The findings are highly suggestive for reoccurrence of lymphosarcoma with generalized lymphadenomegaly of all pictured lymph nodes. Recommend FNA sampling for further definition.

There is a left thyroid mass and the top differential is (non)functional thyroid carcinoma or less likely adenoma.

SEX

Spayed Female

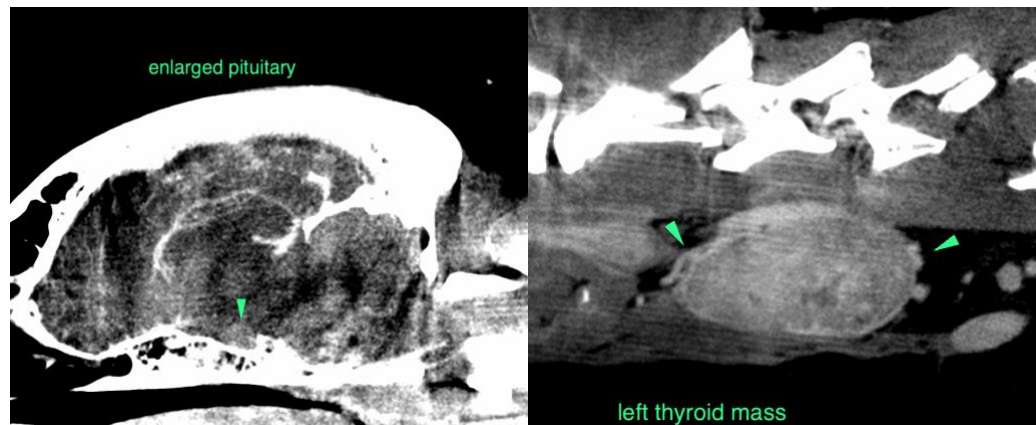
The enlarged pituitary gland in combination with the history of hyperadrenocorticism is highly suggestive for functional pituitary adenoma.

AGE

15 Years

INTERPRETED BY

Sebastian Schaub,
DVM Dr. med. vet.
DipECVDI

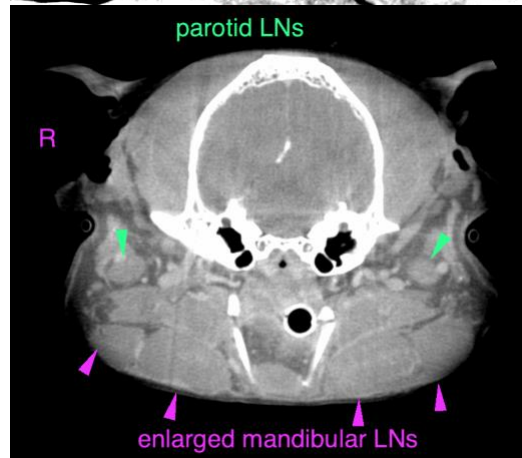


HOSPITAL NAME

Andover AH

REFERRING VET

Dr. Shelley Parker



INVOICE

13791

DATE

10/15/21

The information and recommendations provided are based on the images presented by the



PATIENT referring veterinarian. No evaluation can be communicated regarding pathology that was not visible in the image/video clips provided.

Claire Trotta

Thank you for this referral. If the clinical or image interpretation does not parallel your findings or if I can be of any further assistance please contact me.

SPECIES

Canine

Sebastian Schaub, Sebastian Schaub, DVM, Dr. med. vet. DipECVDI
sebast.schaub@gmail.com

BREED

Beagle Mix

SEX

Spayed Female

AGE

15 Years

INTERPRETED BY

Sebastian Schaub,
DVM Dr. med. vet.
DipECVDI

HOSPITAL NAME

Andover AH

REFERRING VET

Dr. Shelley Parker

INVOICE

13791

DATE

10/15/21