



**PATIENT**

Guiness Vigliotti

**PRESENTING CLINICAL SIGNS**

Ataxia of hind limbs. No proprioception of left hind. Pain response at palpation of mid-spine.  
Abnormal PE/Chem/CBC/UA Results:

**SPECIES**

Canine

**RADIOGRAPHIC STUDY OF THE THORACIC SPINE**

Radiographs of the thoracic spine in three imaging planes are provided for review.

**BREED**

Daschund

**RADIOGRAPHIC FINDINGS**

Mineralized material is superimposed on the intervertebral disc space T10/T11.

Superimposed on the neuroforamen T11/T12 and T12/T13, a convex shaped mineral opacity is seen.

The intervertebral disc space T12/T13 is mildly narrowed.

**SEX**

Male

Multifocal spondylosis formation is seen

The soft tissue shadow of the caudal vena cava is significantly dilated and tortuous; measuring up to 2.6 cm in diameter.

**AGE**

13 Years

**RADIOGRAPHIC DIAGNOSIS**

- Discopathy T13/L1
- Suspect intervertebral disc protrusion T11/T12 & T12/T13
- Chondroid disc degeneration T10/T11
- Spondylosis deformans

**INTERPRETED BY**

Sebastian Schaub, DVM  
Dr. med. vet. DipECVDI

**INTERPRETATION OF THE FINDINGS & FURTHER RECOMMENDATIONS**

The narrowed intervertebral disc space T13/L1 is suggestive for discopathy that might or might not be associated with compressive myelopathy. The convex shaped material superimposed on the neuroforamina T11/T12 and T12/T13 can present mild mineralized protruding disc material that can contribute to clinical signs.

There is significant dilation of the caudal vena cava without signs of pleural or abdominal effusion. Due to the age of the patient, rule out (partial) thrombosis or neoplasia invading the caudal vena cava. Complementing workup by a cardiac echo is recommended.

**HOSPITAL NAME**

The Pet Hospital of  
Stratford

**REFERRING VET**

Dr. Claudia Giuliani,  
DVM

**INVOICE**

54606

**DATE**

10-14-22



**PATIENT**

Guiness Vigliotti

**SPECIES**

Canine

**BREED**

Daschund

**SEX**

Male

**AGE**

13 Years

**INTERPRETED BY**

Sebastian Schaub, DVM  
Dr. med. vet. DipECVDI

**HOSPITAL NAME**

The Pet Hospital of  
Stratford

**REFERRING VET**

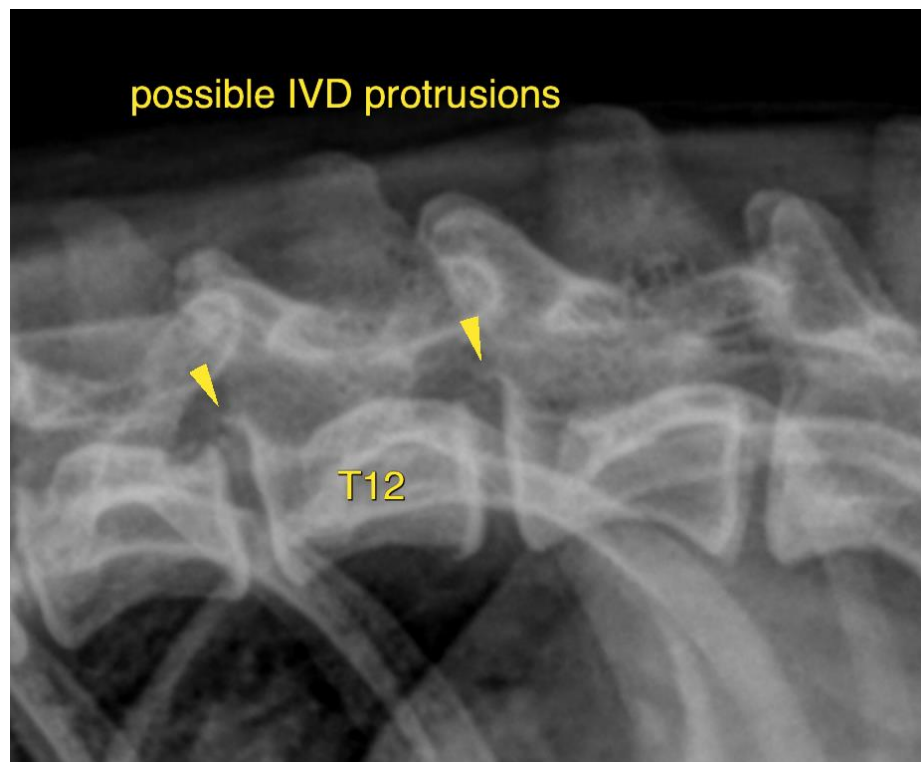
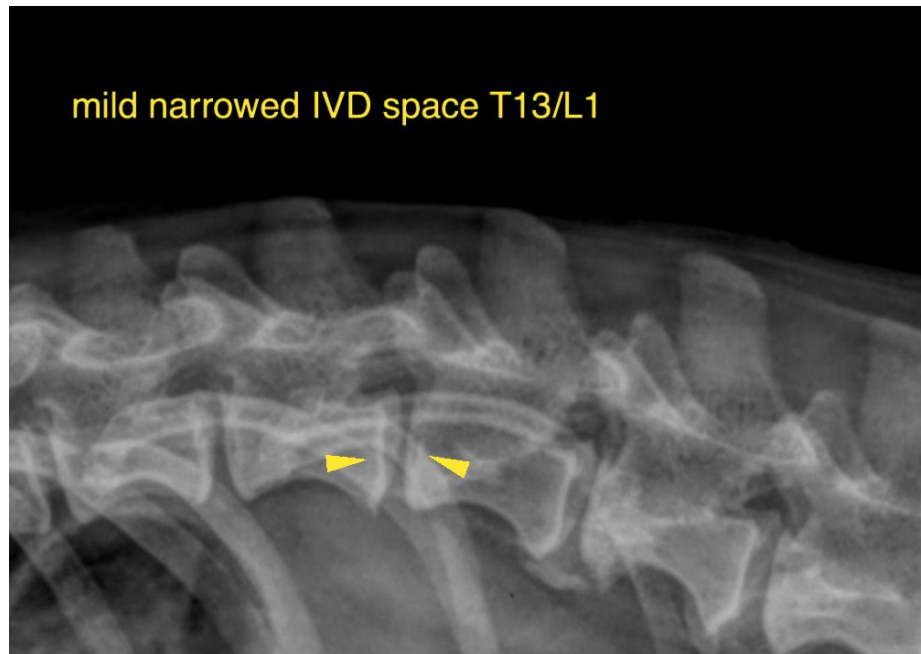
Dr. Claudia Giuliani,  
DVM

**INVOICE**

54606

**DATE**

10-14-22





**PATIENT**

Guiness Vigliotti

**SPECIES**

Canine

**BREED**

Daschund

**SEX**

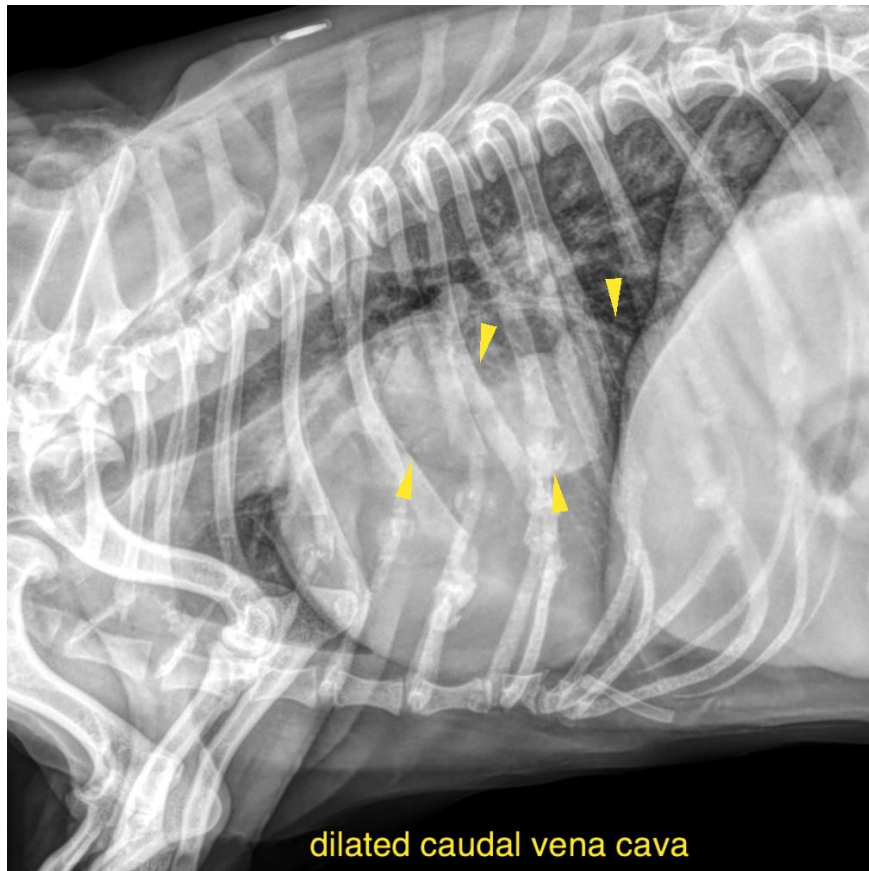
Male

**AGE**

13 Years

**INTERPRETED BY**

Sebastian Schaub, DVM  
Dr. med. vet. DipECVDI



**HOSPITAL NAME**

The Pet Hospital of  
Stratford

**REFERRING VET**

Dr. Claudia Giuliani,  
DVM

**INVOICE**

54606

**DATE**

10-14-22

The information and recommendations provided are based on the images presented by the referring veterinarian/sonographer. No evaluation can be communicated regarding pathology that was not visible in the image/video clips provided.

Thank you for this referral. If the clinical or image interpretation does not parallel your findings or if I can be of any further assistance please contact me.

**Sebastian Schaub**, Sebastian Schaub, DVM, Dr. med. vet. DipECVDI  
sebast.schaub@gmail.com