



**PATIENT PRESENTING CLINICAL SIGNS**

**PATIENT** Zoey Mcguire  
**SPECIES** Canine  
**BREED** Chihuahua

History: Chronic cough that seems to occur after going up stairs. Happens approximately once daily. Responds to diphenoxylate with atropine (Iomitol), but owner does not give on a regular basis due to patient being on so many other medications (has idiopathic epilepsy, osteoarthritis, hypothyroidism as well). On Keppra, potassium bromide, Rimadyl prn, levothyroxine, and diazepam as needed. Owner interested in pursuing MRI but neurologist wants to rule out significant pulmonary disease for cause of the chronic cough prior to anesthesia.

Abnormal PE/Chem/CBC/UA Results: No new findings on physical exam other than weight loss (working on this) as patient is obese. Heart ausculted normally. No crackles, wheezes, or coughing on exam. On diazepam for appointment as patient seizes with stressful events. Saw a metal foreign object in upper GI tract. Owner did not have any idea that she ate anything!

**RADIOGRAPHIC STUDY OF THE THORAX**

**SEX** Spayed Female

Radiographs of the thorax in three imaging planes are provided for review.

**RADIOGRAPHIC FINDINGS**

**AGE** 5 Years 9 Months

The body condition score is 8/9.

The caudal rib pairs present moderate degenerative changes of the costal cartilages and a s-shaped conformation of the costal cartilages.

**INTERPRETED BY**

Sebastian Schaub, DVM Dr. med. vet. DipECVDI

The extrathoracic soft tissues present homogeneous without abnormalities.

The heart is of normal size and shape, there is no evidence of cardiac chamber or vascular enlargement. The pulmonary vasculature is within normal limits.

**HOSPITAL NAME**

Gentle Doctor AH

The cranial mediastinum presents the expected soft tissue opacity. The mediastinal width is less than twice the width of the vertebral column at the same level.

The trachea is normal in diameter and presents the anticipated course. The luminal outline of the trachea is smooth.

**REFERRING VET**

Taylor Morrison

The bronchial tree presents with thin walls and tapers uniformly towards the periphery as expected.

The lung parenchyma presents the expected architecture and opacity; the intrapulmonary vascular branching is seen up to the third order lung vessels.

**INVOICE**

13762

The diaphragm is well delineated with even surface and the expected mild cranial bulging of the diaphragmatic cupola.

**DATE**

10/14/21

A metal opaque curled up linear foreign body is superimposed on the pyloric region of the stomach



**PATIENT**

Zoey Mcguire

**RADIOGRAPHIC DIAGNOSIS**

- Obesity
- Mild congenital deformity of the costal cartilages caudal rib pairs
- Linear metal opaque gastric foreign body
- Hepatomegaly

**SPECIES**

Canine

**INTERPRETATION OF THE FINDINGS & FURTHER RECOMMENDATIONS**

**BREED**

Chihuahua

The radiographic study of the thorax presents without clinically relevant pathology or changes explaining the history of cough.

**SEX**

Spayed Female

**AGE**

5 Years 9 Months

**INTERPRETED BY**

Sebastian Schaub,  
DVM Dr. med. vet.  
DipECVDI

**HOSPITAL NAME**

Gentle Doctor AH

**REFERRING VET**

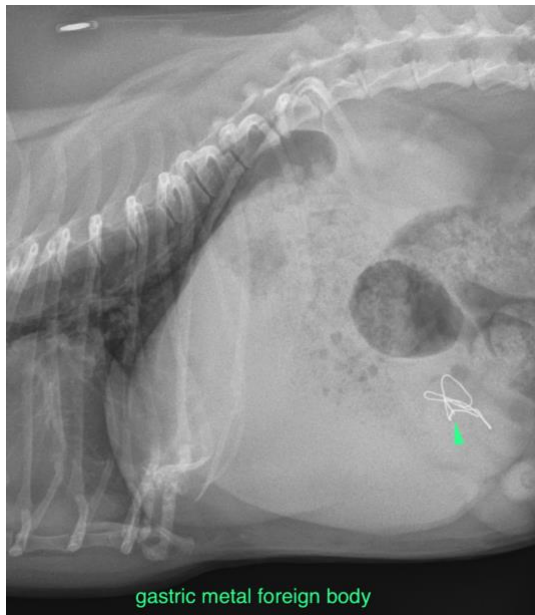
Taylor Morrison

**INVOICE**

13762

**DATE**

10/14/21



**The information and recommendations provided are based on the images presented by the referring veterinarian. No evaluation can be communicated regarding pathology that was not visible in the image/video clips provided.**

Thank you for this referral. If the clinical or image interpretation does not parallel your findings or if I can be of any further assistance please contact me.

Sebastian Schaub, Sebastian Schaub, DVM, Dr. med. vet. DipECVDI  
sebast.schaub@gmail.com



**PATIENT**

Zoey Mcguire

**SPECIES**

Canine

**BREED**

Chihuahua

**SEX**

Spayed Female

**AGE**

5 Years 9 Months

**INTERPRETED BY**

Sebastian Schaub,  
DVM Dr. med. vet.  
DipECVDI

**HOSPITAL NAME**

Gentle Doctor AH

**REFERRING VET**

Taylor Morrison

**INVOICE**

13762

**DATE**

10/14/21