



PATIENT PRESENTING CLINICAL SIGNS

Flossy Joseph History: Continually leaking urine from a very early age. All else wnl
Abnormal PE/Chem/CBC/UA Results:

SPECIES COMPUTED TOMOGRAPHIC STUDY OF THE ABDOMEN

Canine A high resolution pre- and post-contrast CT study of the abdomen is provided for review.

COMPUTED TOMOGRAPHIC FINDINGS

BREED

Golden Retriever The serosal fat presents normal attenuation behavior. There is no evidence of peritoneal effusion or peritonitis.

SEX

Female

Both kidneys present within normal limits for size, shape and organ architecture. After contrast administration a bilaterally symmetric and uniform nephro- and pyelogram is noted. The most distal segment of the right ureter is mildly dilated, measuring up to 3.5 mm in diameter. The right ureter is coursing caudally beyond the margins of the field of view and the orifice is not appreciated. The left ureter is terminating in the urinary bladder approximately 7 mm cranial to the vesicourethral junction. Contrast media is noted in the urethra.

AGE

12 Weeks

The adrenal glands are within normal limits for size, shape and organ architecture.

Both liver and spleen present with normal shape, even surface, uniformly attenuating parenchyma and homogeneous contrast enhancement, unremarkable.

INTERPRETED BY

Sebastian Schaub,
DVM Dr. med. vet.
DipECVDI

The portal vein presents a normal order of its tributary veins and intrahepatic branching. No abnormal vessel is noted inside and outside of the liver parenchyma.

The pancreas is evenly contoured, the pancreatic parenchyma is homogeneous and presents uniform contrast enhancement.

HOSPITAL NAME

Adelaide Plains VS

The position, delineation, wall and content of the gastrointestinal tract are considered within normal limits throughout.

REFERRING VET

John Kataski

The bony and surrounding soft tissue structures reveal no abnormalities.

COMPUTED TOMOGRAPHIC DIAGNOSIS

- Right sided ureteral ectopia

INVOICE

13743

INTERPRETATION OF THE FINDINGS & FURTHER RECOMMENDATIONS

DATE

10/14/21



PATIENT

Flossy Joseph

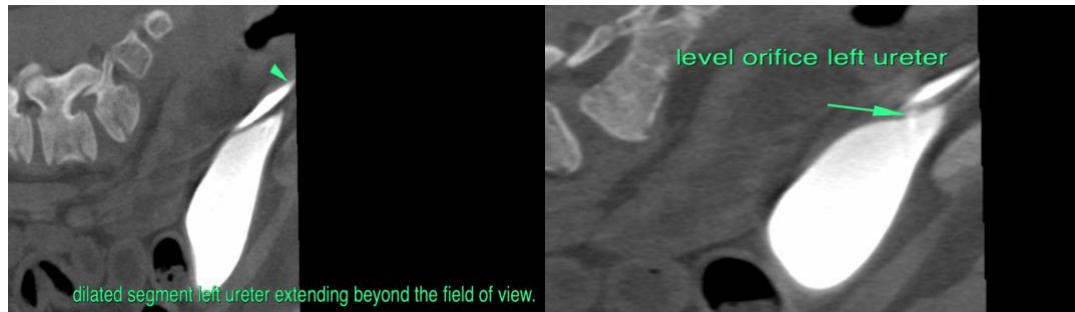
The findings are consistent with right sided ectopic ureter, being a plausible explanation for the clinical signs. The left ureter enters the urinary bladder wall cranial to the urinary bladder neck, however an intramural course cannot be ruled out entered by CT.

SPECIES

Canine

BREED

Golden Retriever



SEX

Female

The information and recommendations provided are based on the images presented by the referring veterinarian. No evaluation can be communicated regarding pathology that was not visible in the image/video clips provided.

AGE

12 Weeks

Thank you for this referral. If the clinical or image interpretation does not parallel your findings or if I can be of any further assistance please contact me.

Sebastian Schaub, Sebastian Schaub, DVM, Dr. med. vet. DipECVDI
sebast.schaub@gmail.com

INTERPRETED BY

Sebastian Schaub,
DVM Dr. med. vet.
DipECVDI

HOSPITAL NAME

Adelaide Plains VS

REFERRING VET

John Kataski

INVOICE

13743

DATE

10/14/21