



PATIENT

Figgy Harrison

PRESENTING CLINICAL SIGNS

Figgy presented for FRONT RIGHT limb lameness of 4 MONTH duration.

SPECIES

Canine

COMPUTED TOMOGRAPHY OF THE SKULL

A high resolution pre- and post-contrast CT study of the skull front limbs are provided for review.

BREED

Mix

Skull

The pictured parts of the dentition are complete and unremarkable in all jaw quadrants.

SEX

FS

The nasal cavity presents the expected aerated spaces between thin & even conchae and turbinates with smooth mucosal lining.

Both temporomandibular joints present congruent joint spaces with even subchondral bone surfaces and are considered within normal limits.

AGE

9 Years

Both tympanic bullae are aerated, the mucosal lining is not seen, the bony wall is smooth and thin. The external ear canals are within normal limits.

INTERPRETED BY

Sebastian Schaub, DVM
Dr. med. vet. DipECVDI

The brain presents no deviation from normal anatomy and symmetry. The brain parenchyma is homogeneous and within normal limits for attenuation and distribution of contrast enhancement. The ventricular system is non-dilated and symmetric.

The submandibular and medial retropharyngeal lymph nodes are small and elongated with a normal short-to-long-axis-ratio is < 0.5, the attenuation and contrast enhancement pattern is uniform.

HOSPITAL NAME

Animal Surgical
Center

The vertebral endplates C2/C3 present moderate spondylosis formation. Mild central mineralization of multiple intervertebral discs along the cervical spine is seen. The vertebral endplates C7/Th1 present left lateralized spondylosis formation.

REFERRING VET

Rockaway Beach Vet

Front limbs

The region of the brachial plexus bilaterally appears normal.

The right axillary lymph node is prominent in comparison to the contralateral side.

INVOICE

47810

Both shoulder joints present smooth osseous margins and the surrounding soft tissue structures are within normal limits.

The left elbow joints presents with smooth osseous margins and a well-defined medial coronoid process, unremarkable.

DATE

10-14-21

The periarticular bones of the right elbow joint present mild osteophyte new bone formation. The medial coronoid process of the right elbow joint presents a mild heterogeneous sclerosis in comparison to the contralateral limb.



PATIENT

Figgy Harrison

SPECIES

Canine

BREED

Mix

SEX

FS

AGE

9 Years

INTERPRETED BY

Sebastian Schaub, DVM
Dr. med. vet. DipECVDI

HOSPITAL NAME

Animal Surgical
Center

REFERRING VET

Rockaway Beach Vet

INVOICE

47810

DATE

10-14-21

COMPUTED TOMOGRAPHIC DIAGNOSIS

- Mild degenerative osteoarthritis right elbow joint
- Suspect pathology medial coronoid process right elbow joint
- Mild lymphadenopathy right axillary lymph node
- Spondylosis deformans cervical spine
- Normal shoulder joints
- Normal skull

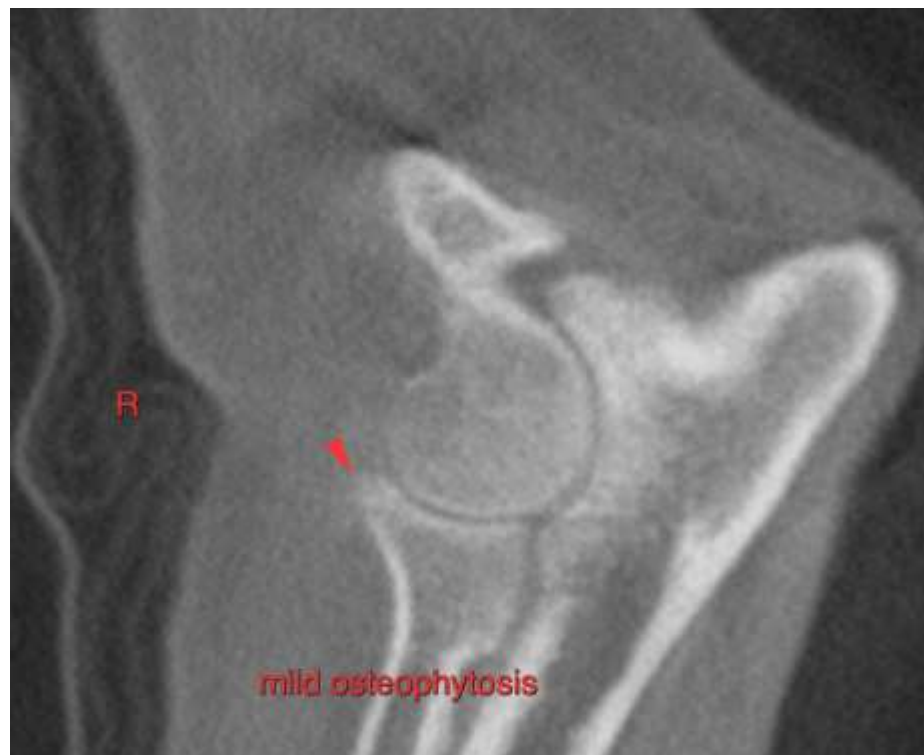INTERPRETATION OF THE FINDINGS & FURTHER RECOMMENDATIONS

The mild degenerative changes of the right elbow joint can be a sequela to pathology of the medial coronoid process. The changes seen are only mild and must be correlated with the findings of the clinical examination – check if pain can be elicited by pressure on the medial compartment of the elbow joint, if so arthroscopy is a consideration.

No additional abnormalities can be appreciated explaining the right front limb lameness. If there is strong clinical suspicion for pathology of the bicipital tendon or rotator cuff injury, workup can be complemented by an ultrasound examination of the right shoulder joint.

No clinically relevant abnormalities of the cervical spine or region of the brachial plexus are noted.

Rule out pathology of the distal segments of the front limb as well.





PATIENT

Figgy Harrison

SPECIES

Canine

BREED

Mix

SEX

FS

AGE

9 Years

INTERPRETED BY

Sebastian Schaub, DVM
Dr. med. vet. DipECVDI

HOSPITAL NAME

Animal Surgical
Center

REFERRING VET

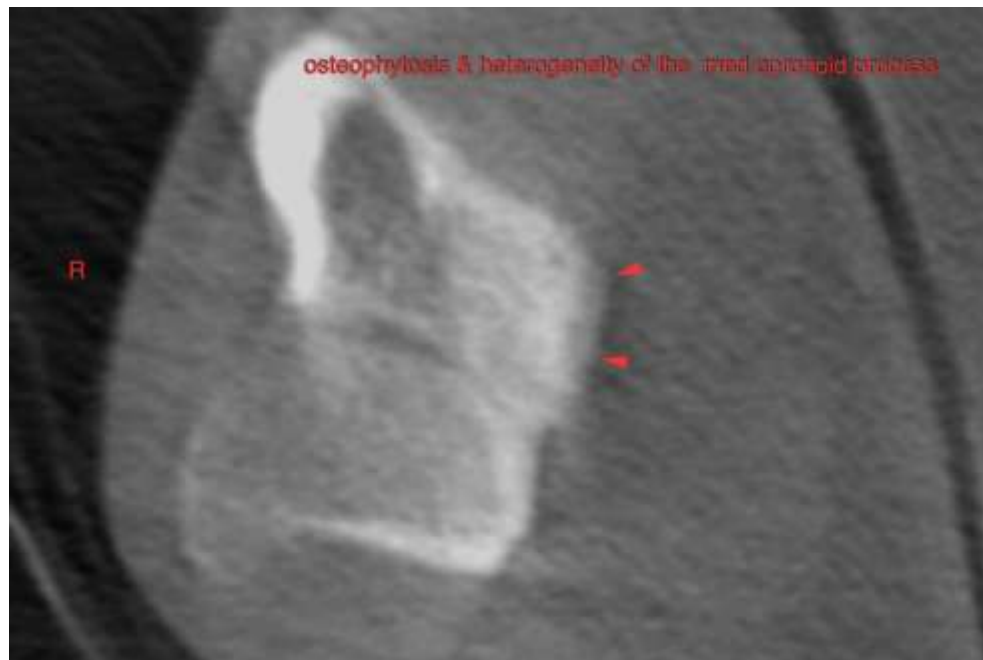
Rockaway Beach Vet

INVOICE

47810

DATE

10-14-21



The information and recommendations provided are based on the images presented by the referring veterinarian. No evaluation can be communicated regarding pathology that was not visible in the image/video clips provided.

Thank you for this referral. If the clinical or image interpretation does not parallel your findings or if I can be of any further assistance please contact me.

Sebastian Schaub, Sebastian Schaub, DVM, Dr. med. vet. DipECVDI
sebast.schaub@gmail.com