



PATIENT PRESENTING CLINICAL SIGNS

Tank Butler History: last week tank started to cough excessively early morning and sometimes at night. Very mild grade heart murmur grade 1 heart murmur can be auscultated on and off. there's a wheeze lung sound. previous xray has been done last year, showed bronchial collapse. attached to you is the previous xray report. Need to rule out heart abnormality or chest abnormality

SPECIES

Canine

RADIOGRAPHIC STUDY OF THE THORAX

BREED

Radiographs of the thorax in three imaging planes are provided for review.

PUG

RADIOGRAPHIC FINDINGS

The body condition score is 7/9.

SEX

Male

Multifocal mild spondylosis formation is seen along the caudal thoracic spine.

The extrathoracic soft tissues present homogeneous without abnormalities.

AGE

14 Years

The heart is of normal size and shape, there is no evidence of cardiac chamber or vascular enlargement. The pulmonary vasculature is within normal limits.

The cranial mediastinum presents the expected soft tissue opacity. The mediastinal width is less than twice the width of the vertebral column at the same level.

INTERPRETED BY

Sebastian Schaub,
DVM Dr. med. vet.
DipECVDI

A soft tissue membrane is bulging ventrally into the lumen of the cervical tracheal segment.

A mild increased visibility of the bronchial walls is appreciated.

HOSPITAL NAME

Truscott AH

The lung parenchyma presents a generalized mild ground glass opacity.

The diaphragm is well delineated with even surface and the expected mild cranial bulging of the diaphragmatic cupola.

REFERRING VET

Dr. Medhat Meawad

RADIOGRAPHIC DIAGNOSIS

- Mild broncho-interstitial lung pattern
- Redundant tracheal membrane
- Mild obesity
- Spondylosis deformans

INVOICE

17719

INTERPRETATION OF THE FINDINGS & FURTHER RECOMMENDATIONS

The bronchial lung pattern is suggestive for bronchitis and primary inflammatory non-infectious causes – such as lymphocytic plasmocytic, eosinophilic, mixed – and infectious causes (e.g. viral,

DATE

10/13/22



PATIENT Tank Butler
 bacterial, parasitic) need to be considered. The interstitial component of the lung pattern is likely a sequela to age related changes of the lung and the mild obesity of the patient. The acute onset of clinical signs is increasing the odds for infectious origin of bronchitis. Empirical diagnostic therapy versus lower airway sampling can be considered.

SPECIES Canine
 The redundant tracheal membrane can be a precursor for tracheal collapse. In the current radiographic study of the thorax, no bronchial collapse is appreciated.

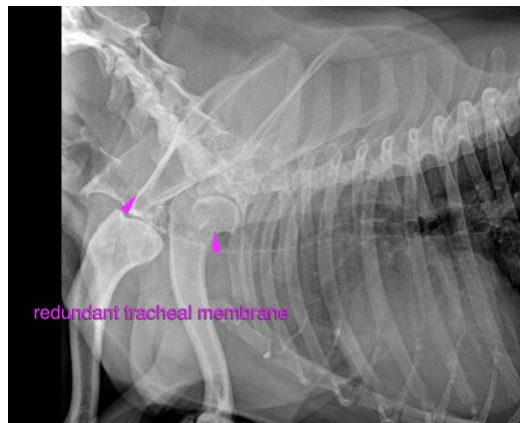
Canine

BREED

Pug

SEX

Male



AGE

14 Years

The information and recommendations provided are based on the images presented by the referring veterinarian/sonographer. No evaluation can be communicated regarding pathology that was not visible in the image/video clips provided.

INTERPRETED BY

Thank you for this referral. If the clinical or image interpretation does not parallel your findings or if I can be of any further assistance please contact me.

Sebastian Schaub,
 DVM Dr. med. vet.
 DipECVDI

Sebastian Schaub, Sebastian Schaub, DVM, Dr. med. vet. DipECVDI
 sebast.schaub@gmail.com

HOSPITAL NAME

Truscott AH

REFERRING VET

Dr. Medhat Meawad

INVOICE

17719

DATE

10/13/22