



**PATIENT PRESENTING CLINICAL SIGNS**

Girl Calman History: Unknown trauma four to five days ago. Right pelvic limb lameness. No overt neuro signs noted.

**SPECIES RADIOGRAPHIC STUDY OF THE PELVIS**

Feline Radiographs of the pelvis in two orthogonal imaging planes are provided for review.

**RADIOGRAPHIC FINDINGS**

**BREED**

DSH

The osseous structures of the pelvis are within normal limits. The intervertebral disc space between the first and second caudate vertebra is collapsed. There is left lateral subluxation of the second caudate vertebra.

**SEX**

Spayed Female

The right thigh musculature is moderately swollen in comparison to the contralateral limb. The right femur presents without abnormalities.

**RADIOGRAPHIC DIAGNOSIS**

**AGE**

3 Years

- Soft tissue swelling right thigh musculature
- Left lateral subluxation second caudate vertebra

**INTERPRETATION OF THE FINDINGS & FURTHER RECOMMENDATIONS**

**INTERPRETED BY**

Sebastian Schaub,  
DVM Dr. med. vet.  
DipECVDI

The soft tissue swelling of the right thigh musculature in combination with the history of potential trauma is suggestive for hematoma secondary to contusion without evidence of femoral fracture. Theoretically abscess or empyema formation is a potential – no signs of gas, correlate with presenting clinical signs. In case of doubt, recommend complementing workup by an ultrasound examination of the right thigh musculature.

**HOSPITAL NAME**

Friendship Spring VC

The clinical relevance of the subluxation of Cd2 is unclear and can be a chronic finding as there appears to be smooth new bone formation and no overt soft tissue swelling is appreciated at the same level.

**REFERRING VET**

Trae Cutchin

**INVOICE**

17728

**DATE**

10/13/22



**PATIENT**

Girl Calman

**SPECIES**

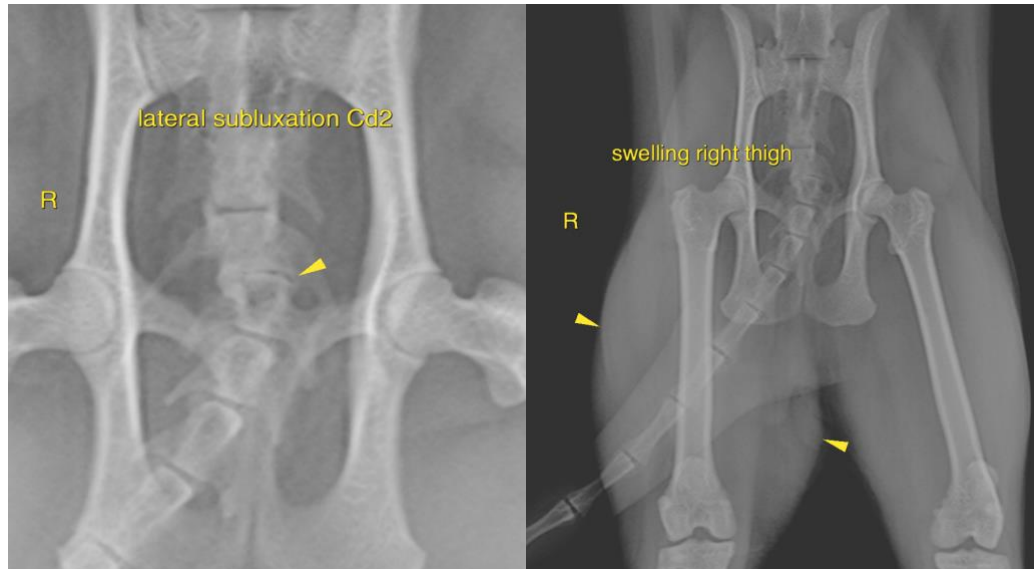
Feline

**BREED**

DSH

**SEX**

Spayed Female



**AGE**

3 Years

The information and recommendations provided are based on the images presented by the referring veterinarian/sonographer. No evaluation can be communicated regarding pathology that was not visible in the image/video clips provided.

Thank you for this referral. If the clinical or image interpretation does not parallel your findings or if I can be of any further assistance please contact me.

**INTERPRETED BY**

Sebastian Schaub,  
DVM Dr. med. vet.  
DipECVDI

**Sebastian Schaub**, Sebastian Schaub, DVM, Dr. med. vet. DipECVDI  
sebast.schaub@gmail.com

**HOSPITAL NAME**

Friendship Spring VC

**REFERRING VET**

Trae Cutchin

**INVOICE**

17728

**DATE**

10/13/22