



PATIENT PRESENTING CLINICAL SIGNS

Elmo Cathey History: lesion bridging LS junction - r/o neoplasia, IVDD, spondylosis, other. note concern for neoplasia from one radiologist though primary radiologist describes this as IVDD/spondylosis-marked.

SPECIES Abnormal PE/Chem/CBC/UA Results:

Canine RADIOGRAPHIC STUDY OF THE PELVIS

BREED Radiographs of the pelvis in two orthogonal imaging planes are provided for review. Images are provided in JPEG file format.

Golden Retriever RADIOGRAPHIC FINDINGS

SEX The facet joints L3/L4 and L4/L5 present moderate osteophyte new bone formation.

Neutered Male The vertebral endplates of the lumbosacral junction present moderate to marked spondylosis formation. The right coxofemoral joint presents mild osteophyte formation at the transition between the femoral head and neck.

AGE RADIOGRAPHIC DIAGNOSIS

- 12 Years 9 Months**
- Advanced spondylosis formation lumbosacral junction
 - Mild degenerative osteoarthritis right coxofemoral joint
 - SPondyloarthritis L3/L4&L4/L5

INTERPRETED BY

Sebastian Schaub,
DVM Dr. med. vet.
DipECVDI

INTERPRETATION OF THE FINDINGS & FURTHER RECOMMENDATIONS

The findings are compatible with advanced spondylosis formation of the lumbosacral junction ± discopathy. Based on clinical signs, cross-sectional imaging can be used to screen if there is accompanying clinically relevant discopathy.

HOSPITAL NAME

Mt. Yonah AH

REFERRING VET

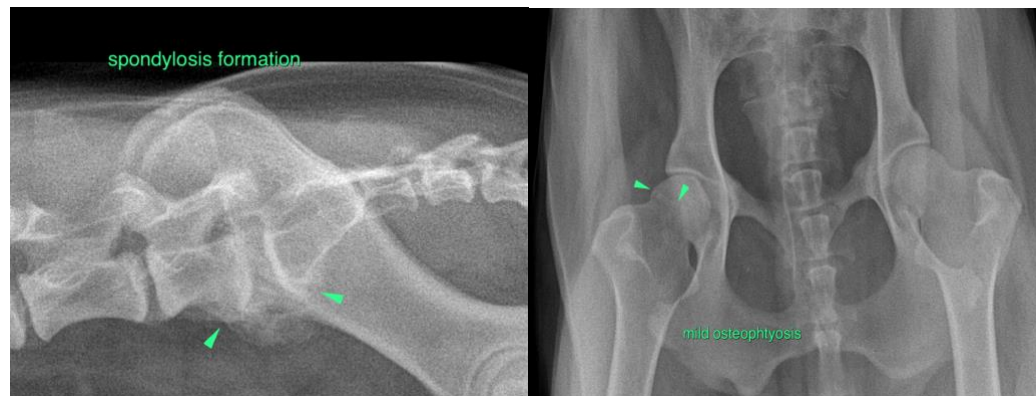
Dr. Rachel Eddleman

INVOICE

13733

DATE

10/13/21





PATIENT

Elmo Cathey

The information and recommendations provided are based on the images presented by the referring veterinarian. No evaluation can be communicated regarding pathology that was not visible in the image/video clips provided.

SPECIES

Canine

Thank you for this referral. If the clinical or image interpretation does not parallel your findings or if I can be of any further assistance please contact me.

Sebastian Schaub, Sebastian Schaub, DVM, Dr. med. vet. DipECVDI
sebast.schaub@gmail.com

BREED

Golden Retriever

SEX

Neutered Male

AGE

12 Years 9 Months

INTERPRETED BY

Sebastian Schaub,
DVM Dr. med. vet.
DipECVDI

HOSPITAL NAME

Mt. Yonah AH

REFERRING VET

Dr. Rachel Eddleman

INVOICE

13733

DATE

10/13/21