



**PATIENT**

Fable Haas

**PRESENTING CLINICAL SIGNS**

Limping on left rear leg since Friday. Gets worse with exercise. Having a hard time getting up. Happened after playing catch.  
Abnormal PE/Chem/CBC/UA Results: PAIN AND CRANIAL DRAWER IN LEFT STIFLE

**SPECIES**

Canine

**RADIOGRAPHIC STUDY OF THE PELVIS AND STIFLE JOINTS**

A complete set of radiographs of the pelvis and the stifle joints is provided for review.

**BREED**

Labrador Retriever  
Mix

**RADIOGRAPHIC FINDINGS**

The osseous and surrounding soft tissue structures of the pelvis are within normal limits. Both coxofemoral joints present smooth osseous margins and congruent joint spaces.

The periarticular bones of the left stifle joint present moderate osteophyte new bone formation and a moderate intracapsular soft tissue swelling is appreciated, effacing the infrapatellar fat-pad cranially and the fascial plane caudally.

**SEX**

Female

The periarticular bones of the right stifle joint present mild osteophyte formation at the proximal aspect of the femoral trochlear ridge and a mild intracapsular soft tissue swelling of the right stifle joint is appreciated.

**AGE**

7 Years

**RADIOGRAPHIC DIAGNOSIS**

- Degenerative osteoarthritis stifle joints bilaterally, L>R
- Articular swelling stifle joints bilaterally, L>R
- Normal pelvis & coxofemoral joints

**INTERPRETED BY**

Sebastian Schaub, DVM  
Dr. med. vet. DipECVDI

**INTERPRETATION OF THE FINDINGS & FURTHER RECOMMENDATIONS**

The radiographic study is consistent with bilateral chronic degenerative osteoarthritis with concomitant joint effusion of both stifle joints, L>>R. The most-likely underlying cause is (partial) rupture of the cranial cruciate ligament with or without meniscal disease.

**HOSPITAL NAME**

Elizabeth Animal  
Hospital

A positive drawer sign or tibial compression test under general anesthesia can be used to confirm the diagnosis.

**REFERRING VET**

Kim Allyn, DVM

**INVOICE**

54594

**DATE**

10-12-22



**PATIENT**

Fable Haas

**SPECIES**

Canine

**BREED**

Labrador Retriever  
Mix

**SEX**

Female

**AGE**

7 Years

**INTERPRETED BY**

Sebastian Schaub, DVM  
Dr. med. vet. DipECVDI

**HOSPITAL NAME**

Elizabeth Animal  
Hospital

**REFERRING VET**

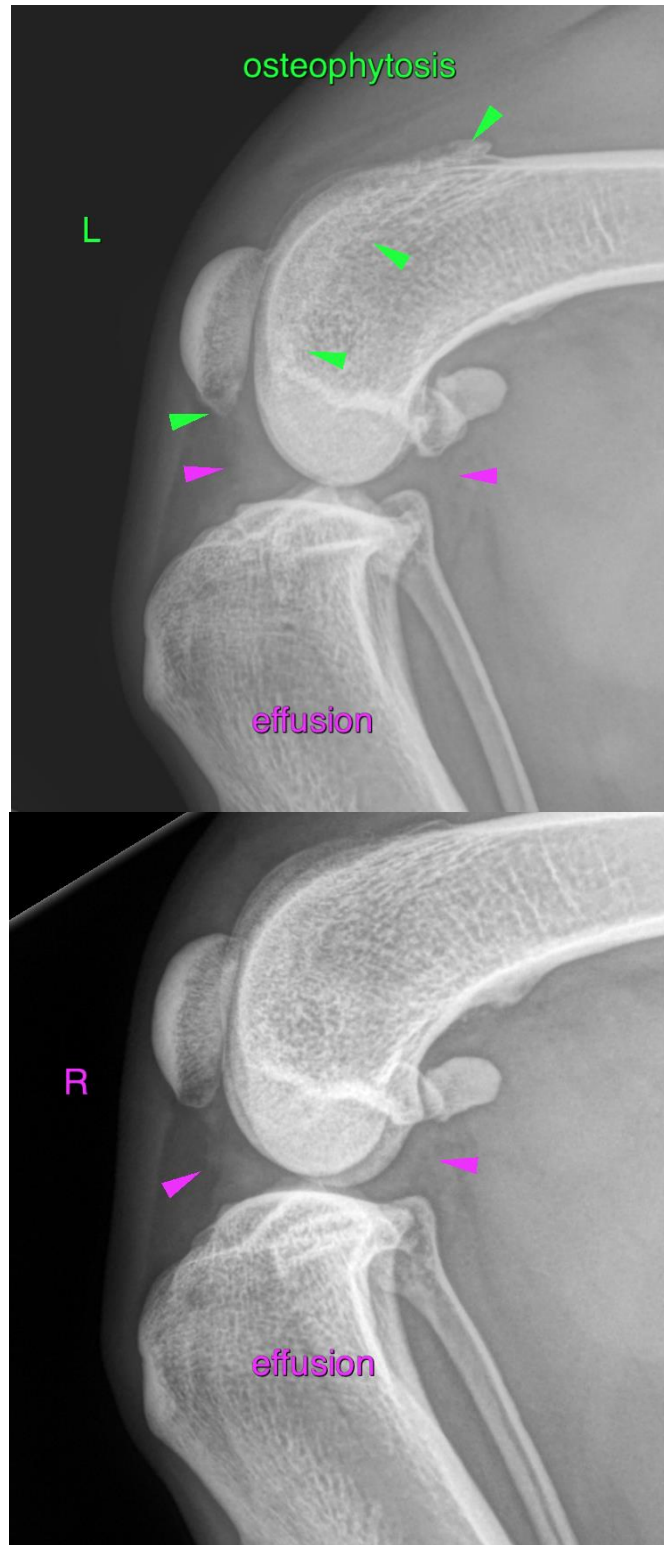
Kim Allyn, DVM

**INVOICE**

54594

**DATE**

10-12-22





**PATIENT**

Fable Haas

**SPECIES**

Canine

**BREED**

Labrador Retriever  
Mix

The information and recommendations provided are based on the images presented by the referring veterinarian/sonographer. No evaluation can be communicated regarding pathology that was not visible in the image/video clips provided.

Thank you for this referral. If the clinical or image interpretation does not parallel your findings or if I can be of any further assistance please contact me.

**SEX**

Female

**Sebastian Schaub**, Sebastian Schaub, DVM, Dr. med. vet. DipECVDI  
sebast.schaub@gmail.com

**AGE**

7 Years

**INTERPRETED BY**

Sebastian Schaub, DVM  
Dr. med. vet. DipECVDI

**HOSPITAL NAME**

Elizabeth Animal  
Hospital

**REFERRING VET**

Kim Allyn, DVM

**INVOICE**

54594

**DATE**

10-12-22