



#### PATIENT

Lulu Terlizzi

#### PRESENTING CLINICAL SIGNS

History: Pt came back from being chased by other dogs limping LPL about 3 wk ago. No abnormalities noted on physical at that time. She sometimes seems normal and sometimes still limps. She was here for a COHAT today and owner requested we take LPL rads while she was sedated. She sometimes internally rotates the tarsus and had slight discomfort on aggressive lateral malleolar/collateral manipulation. Otherwise seems wnl.

#### SPECIES

Canine

Abnormal PE/Chem/CBC/UA Results: WNL

#### BREED

Poodle

#### RADIOGRAPHIC STUDY OF THE TARSAL JOINTS

Radiographs of the tarsal joints in two imaging planes are provided for review.

#### RADIOGRAPHIC FINDINGS

#### SEX

Spayed Female

Both tarsal joints presents smooth osseous margins and without evidence of periarticular soft tissue swelling.

#### RADIOGRAPHIC DIAGNOSIS

#### AGE

10 Years

- Normal tarsal joints

#### INTERPRETATION OF THE FINDINGS & FURTHER RECOMMENDATIONS

The radiographic study presents without abnormalities of the tarsal joints. The mild irregularity of the lateral malleolus is still considered as normal conformation. No soft tissue swelling, sclerosis or osteophytosis/periosteal new bone formation is appreciated which is expected in case of chronic malleolar pathology. Anyway, pathology of the lateral collateral ligament – such as distortion might be a potential.

#### INTERPRETED BY

Sebastian Schaub,  
DVM Dr. med. vet.  
DipECVDI

**The information and recommendations provided are based on the images presented by the referring veterinarian. No evaluation can be communicated regarding pathology that was not visible in the image/video clips provided.**

#### HOSPITAL NAME

Sierra Pet Clinic

Thank you for this referral. If the clinical or image interpretation does not parallel your findings or if I can be of any further assistance please contact me.

#### REFERRING VET

Dr. Swalander

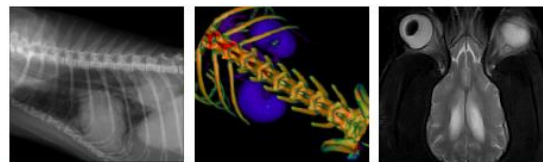
**Sebastian Schaub**, Sebastian Schaub, DVM, Dr. med. vet. DipECVDI  
sebast.schaub@gmail.com

#### INVOICE

13720

#### DATE

10/12/21



**PATIENT**

Lulu Terlizzi

**SPECIES**

Canine

**BREED**

Poodle

**SEX**

Spayed Female

**AGE**

10 Years

**INTERPRETED BY**

Sebastian Schaub,  
DVM Dr. med. vet.  
DipECVDI

**HOSPITAL NAME**

Sierra Pet Clinic

**REFERRING VET**

Dr. Swalander

**INVOICE**

13720

**DATE**

10/12/21