



**PATIENT PRESENTING CLINICAL SIGNS**

**Gunner Peneton** History: Patient had a TPLO on the right hind leg in 2018. And starting Sunday evening patient started limping on hind left leg. Upon examination Ambulatory X 3, TOE TOUCHING ON LEFT HIND, MEDIAL BUTTRESS ON RIGHT HIND FROM PREVIOUS TPLO. PAIN ON EXTENSION OF STIFLE.

**SPECIES**

Abnormal PE/Chem/CBC/UA Results: Pending

Canine

**RADIOGRAPHIC STUDY OF THE STIFLE JOINTS**

**BREED**

A complete set of radiographs of the stifle joints is provided for review.

Labrador Retriever  
Mix

**RADIOGRAPHIC FINDINGS**

The periarticular bones of the right stifle joint present moderate osteophyte new bone formation. A TPLO plate is visible at the medial aspect of the proximal tibia. The osteotomy of the right proximal tibia is filled with trabecular bone. The right stifle joint presents a mild to moderate intraarticular soft tissue swelling.

**SEX**

Neutered Male

The left stifle joints presents a moderate intracapsular soft tissue swelling, distorting the infrapatellar fat pad cranially and the fascial plane caudally. The periarticular bones of the left stifle joint present mild osteophyte new bone formation. A moderate cranial subluxation of the tibia is noted.

**AGE**

9 Years 5 Months

**RADIOGRAPHIC DIAGNOSIS**

**INTERPRETED BY**

- Mild degenerative osteoarthritis left stifle joint
- Moderate articular swelling left stifle joint
- Moderate cranial subluxation left tibi
- History of surgical management of pathology of the right cranial cruciate ligament by TPLO, the osteotomy is in the remodeling phase

Sebastian Schaub,  
DVM Dr. med. vet.  
DipECVDI

**HOSPITAL NAME**

**INTERPRETATION OF THE FINDINGS & FURTHER RECOMMENDATIONS**

Elizabeth AH

The radiographic study of the left stifle joint is compatible with failure of the left cranial cruciate ligament ± meniscal pathology.

**REFERRING VET**

A positive drawer sign or tibial compression test under general anesthesia can be used to confirm the diagnosis.

Kim Allyn, DVM

**INVOICE**

13711

**DATE**

10/12/21



**PATIENT**

Gunner Peneton

**SPECIES**

Canine

**BREED**

Labrador Retriever  
Mix

**SEX**

Neutered Male

**AGE**

9 Years 5 Months

**INTERPRETED BY**

Sebastian Schaub,  
DVM Dr. med. vet.  
DipECVDI

**HOSPITAL NAME**

Elizabeth AH

**REFERRING VET**

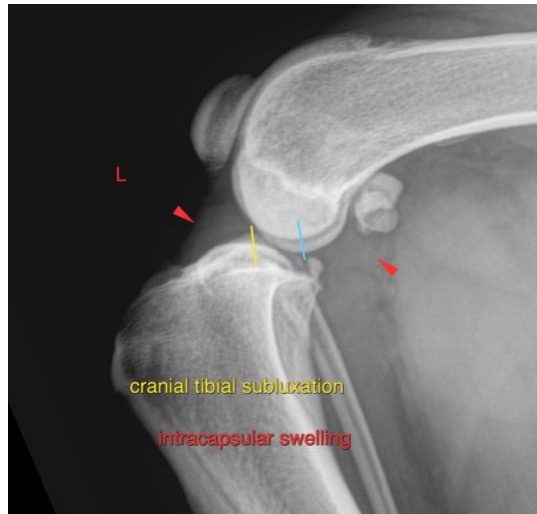
Kim Allyn, DVM

**INVOICE**

13711

**DATE**

10/12/21



**SEX** The information and recommendations provided are based on the images presented by the referring veterinarian. No evaluation can be communicated regarding pathology that was not visible in the image/video clips provided.

**AGE** Thank you for this referral. If the clinical or image interpretation does not parallel your findings or if I can be of any further assistance please contact me.

**INTERPRETED BY** Sebastian Schaub, Sebastian Schaub, DVM, Dr. med. vet. DipECVDI  
sebast.schaub@gmail.com