



PATIENT

Splinter Soda

PRESENTING CLINICAL SIGNS

p has been having a cough that comes and goes x 1 year p has been tested with PCR: had microplasma felia (asthma) p is now coughing again a couple of times a week p is an indoor cat

SPECIES

Feline

RADIOGRAPHIC STUDY OF THE THORAX

Radiographs of the thorax in two orthogonal imaging planes are provided for review.

BREED

Domestic Shorthair

RADIOGRAPHIC FINDINGS

The body condition score is 8/9.

Multifocal mild spondylosis formation is seen along the thoracic spine.

The extrathoracic soft tissues present homogeneous without abnormalities.

SEX

Spayed

The heart is of normal size and shape, there is no evidence of cardiac chamber or vascular enlargement. The pulmonary vasculature is within normal limits.

The trachea is normal in diameter and presents the anticipated course. The luminal outline of the trachea is smooth.

AGE

10 Years

The bronchial tree presents with thin walls and tapers uniformly towards the periphery as expected.

INTERPRETED BY

Sebastian Schaub, DVM
Dr. med. vet. DipECVDI

Level with the 7th intercostal space, a roundish – in the VD view ovoid shaped – homogeneous soft tissue opacity is appreciated in the left caudal lung lobe. A second crescent shaped soft tissue opacity is seen in the lateral view, level with the 8th intercostal space, superimposed on the diaphragm – not appreciated in the VD view.

The diaphragm is well delineated with even surface and the expected mild cranial bulging of the diaphragmatic cupola.

HOSPITAL NAME

Tenafly Vet Center

RADIOGRAPHIC DIAGNOSIS

- Nodular soft tissue opacities left caudal lung lobe
- Obesity
- Spondylosis deformans

REFERRING VET

Ohad Barnea

INTERPRETATION OF THE FINDINGS & FURTHER RECOMMENDATIONS

The nodular soft tissue opacities of the left caudal lung lobe can present regions of round pneumonia, bronchial mucus plugging (unusual course and shape) or primary pulmonary neoplasia. A clinical trial with antimicrobial drugs and follow up radiographs in 3-4 weeks can be considered. A CT study of the thorax can be considered alternatively for further definition.

INVOICE

54550

DATE

10-11-22



PATIENT

Splinter Soda

SPECIES

Feline

BREED

Domestic Shorthair

SEX

Spayed

AGE

10 Years

INTERPRETED BY

Sebastian Schaub, DVM
Dr. med. vet. DipECVDI

HOSPITAL NAME

Tenafly Vet Center

REFERRING VET

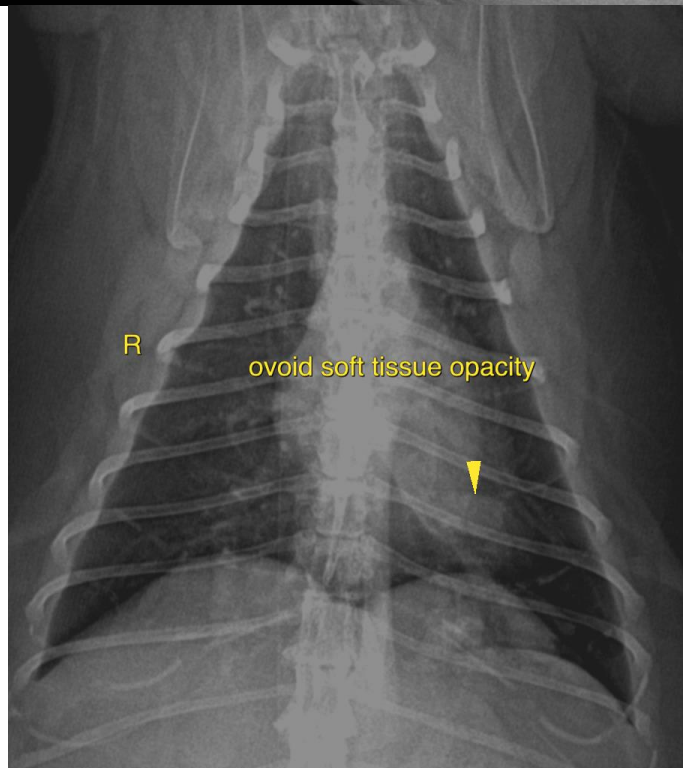
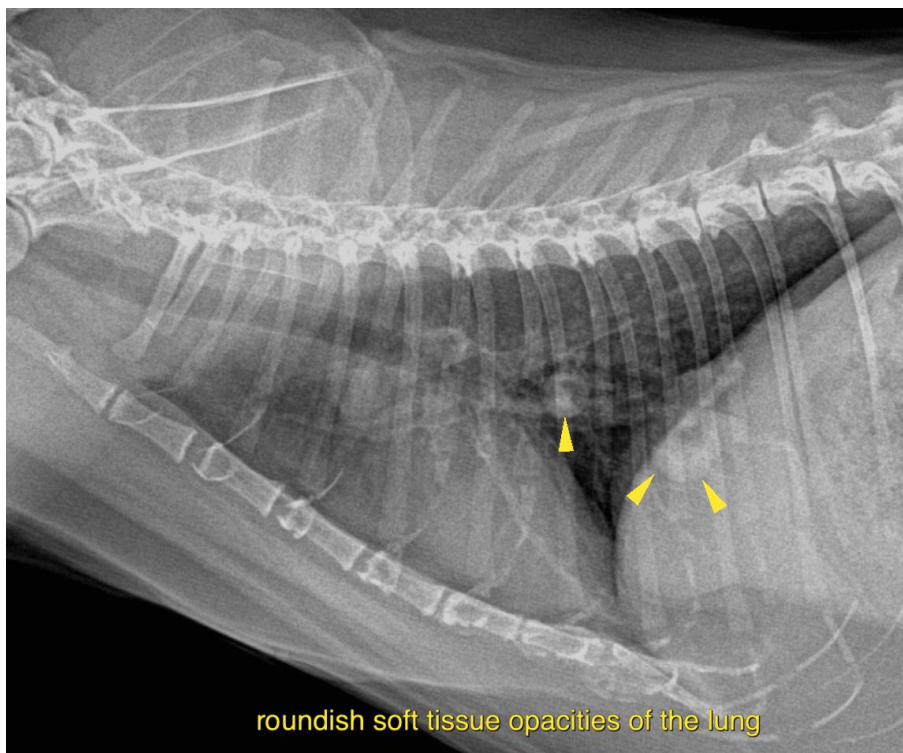
Ohad Barnea

INVOICE

54550

DATE

10-11-22





PATIENT

Splinter Soda

SPECIES

Feline

The information and recommendations provided are based on the images presented by the referring veterinarian/sonographer. No evaluation can be communicated regarding pathology that was not visible in the image/video clips provided.

BREED

Domestic Shorthair

Thank you for this referral. If the clinical or image interpretation does not parallel your findings or if I can be of any further assistance please contact me.

SEX

Spayed

Sebastian Schaub, Sebastian Schaub, DVM, Dr. med. vet. DipECVDI
sebast.schaub@gmail.com

AGE

10 Years

INTERPRETED BY

Sebastian Schaub, DVM
Dr. med. vet. DipECVDI

HOSPITAL NAME

Tenafly Vet Center

REFERRING VET

Ohad Barnea

INVOICE

54550

DATE

10-11-22