



**PATIENT**

Snorky Mastiff to  
Mutts

**PRESENTING CLINICAL SIGNS**

unable to open mouth

**COMPUTED TOMOGRAPHY OF THE SKULL**

A high resolution plain CT study of the skull is provided for review.

**SPECIES**

Canine

**COMPUTED TOMOGRAPHIC FINDINGS**

Triadan 301, 305, 308 and 408 are absent.

**BREED**

French Bulldog

The nasal cavity presents the expected aerated spaces between thin & even conchae and turbinates with smooth mucosal lining.

Both temporomandibular joints present congruent joint spaces with even subchondral bone surfaces and are considered within normal limits.

**SEX**

FI

Between the tympanic bullae and the ramus of the mandible bilaterally, solid new bone formation is emanating from the medial aspect of the ramus of the mandible and coming in contact with the tympanic bullae bilaterally. The osseous lining of the tympanic bullae is breed specific symmetrically thickened and smooth. Both tympanic bullae are filled with uniform soft tissue attenuating material. The external ear canals are within normal limits.

**AGE**

2 Years

The submandibular and medial retropharyngeal lymph nodes are small and elongated with a normal short-to-long-axis-ratio is < 0.5, the attenuation pattern is uniform.

**INTERPRETED BY**

Sebastian Schaub, DVM  
Dr. med. vet. DipECVDI

**COMPUTED TOMOGRAPHIC DIAGNOSIS**

- Bilateral synostosis formation between the ramus of the mandible and the tympanic bulla
- Bilateral otitis media, possibly primary effusive
- Multiple absent teeth

**HOSPITAL NAME**

Animal Surgical  
Center

**INTERPRETATION OF THE FINDINGS & FURTHER RECOMMENDATIONS**

There is bilaterally symmetric new bone formation seen between the ramus of the mandible bilaterally and the tympanic bulla forming synostosis and being a plausible source for the presenting jaw lock. Either form of craniomandibular osteopathy (no signs of periosteal new bone formation along the body of the mandible), otitis media or congenital synostosis are potentials here.

**REFERRING VET**

Rescue

**INVOICE**

54567

**DATE**

10-11-22



**PATIENT**

Snorky Mastiff to  
Mutts

**SPECIES**

Canine

**BREED**

French Bulldog

**SEX**

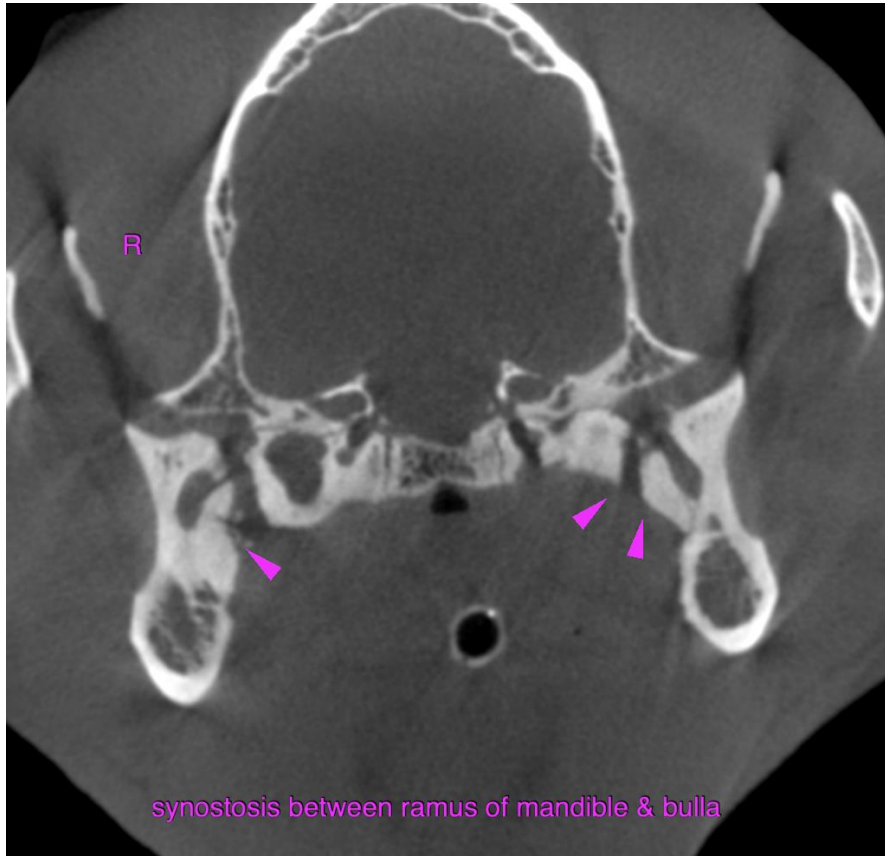
FI

**AGE**

2 Years

**INTERPRETED BY**

Sebastian Schaub, DVM  
Dr. med. vet. DipECVDI



**HOSPITAL NAME**

Animal Surgical  
Center

**REFERRING VET**

Rescue

**INVOICE**

54567

**DATE**

10-11-22

The information and recommendations provided are based on the images presented by the referring veterinarian/sonographer. No evaluation can be communicated regarding pathology that was not visible in the image/video clips provided.

Thank you for this referral. If the clinical or image interpretation does not parallel your findings or if I can be of any further assistance please contact me.

**Sebastian Schaub**, Sebastian Schaub, DVM, Dr. med. vet. DipECVDI  
sebast.schaub@gmail.com