



PATIENT PRESENTING CLINICAL SIGNS

Pinkie Lupu
SPECIES Canine
BREED Australian Shepherd Mini
 Rechecking: vomiting? History: 2yr 7m old SF miniature australian shepherd presented today for a recheck - no improvement. Currently, O says P has not been eating (last meal 2 dasy ago), but did take a few bites of some chicken and did take a treat in the exam room from me. O says she ahs been switching the foods to entice P more. Food bowls are separated from housemate "Milky" per O. O says P is still drinking normally. P has been having diarrhea - last episode was this morning, appearance is brown, no blood and softer in texture NOT liquid. C/S/V/D: vomiting and diarrhea; no other symptoms E/D/U/D: inappetance; defecation abnormal
 Abnormal PE/Chem/CBC/UA Results: Exam Notes: BAR, mm pm, heavily resists oral exam. Unable to open up her mouth. Is acting like trying to get something unstuck from within her mouth....moving tongue around, chewing constantly. Ab Palp - WNL Rectal exam - empty
 Diagnostics & Testing: Sedate with 0.15ml each Dexdomitor/Torb IM to allow for oral exam +/- x-rays

RADIOGRAPHIC STUDY OF THE ABDOMEN

SEX Radiographs of the abdomen in two imaging planes are provided for review.

SF RADIOGRAPHIC FINDINGS

The surrounding bony structures are within normal limits.

AGE No abnormalities of the extraabdominal soft tissues are noted. The abdominal wall is smooth and thin.

2 Years, 7 Months The serosal detail is maintained throughout the peritoneal and retroperitoneal space.

INTERPRETED BY The liver is appropriate in position, size and presents uniform opacity.

Sebastian Schaub, DVM
 Dr. med. vet. DipECVDI The splenic head is in the anticipated position and within normal limits for size and opacity. The splenic body and tail are considered normal for position, size, shape and opacity.

HOSPITAL NAME Both kidneys are seen and present with normal size, shape, delineation and opacity. The urinary bladder is in its anticipated position. No radiopaque calculi are noted throughout the upper and lower urinary tract.

DPC Veterinary Hospital The stomach is in its anticipated position and is empty.

REFERRING VET The small intestinal loops are of even diameter and non-dilated, a small amount of gas is seen within the small intestinal loops and considered within normal limits.

Dr. Feldt The colon is seen in the expected position. The colon is empty, but a small amount of gas and fluid. The colon appears rigid.

RADIOGRAPHIC DIAGNOSIS

- INVOICE**
- Empty adynamic appearing colon
 - Empty stomach
- 54572

INTERPRETATION OF THE FINDINGS & FURTHER RECOMMENDATIONS

DATE 10-11-22
 The overall empty gastrointestinal tract and adynamic appearing stomach in combination with the presenting clinical signs are highly suggestive for gastroenteritis. There is no evidence of radiopaque foreign material or signs for gastrointestinal mechanical obstruction. If clinical signs



PATIENT

Pinky Lupu

are refractory to therapy, recommend follow up radiographs or a complete abdominal ultrasound examination; in some cases a high ileus may lack classical radiographic signs of mechanical obstruction.

SPECIES

Canine

BREED

Australian Shepherd
Mini

SEX

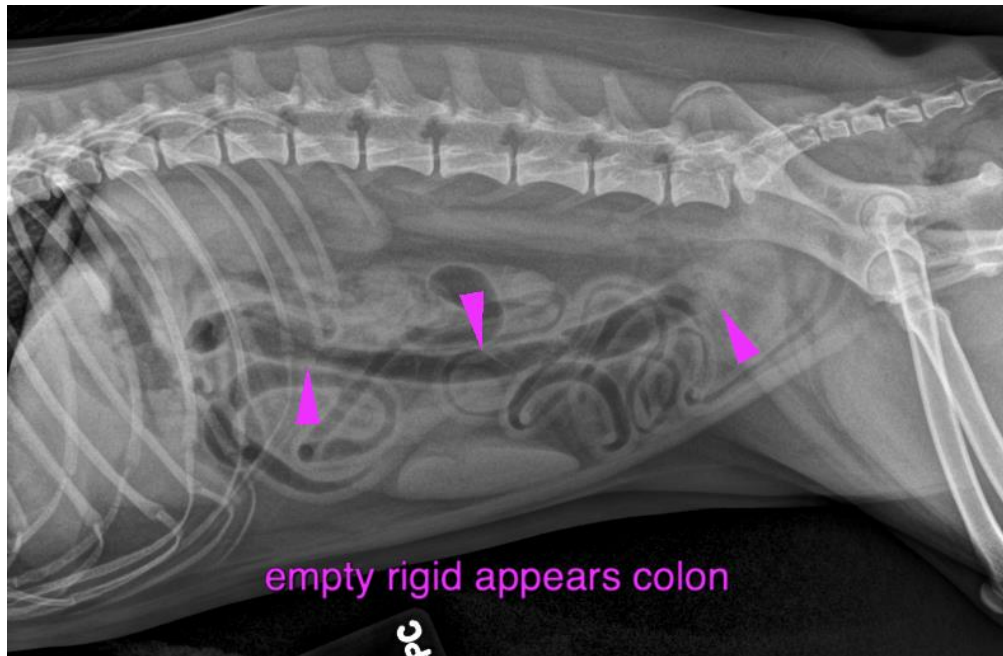
SF

AGE

2 Years, 7 Months

INTERPRETED BY

Sebastian Schaub, DVM
Dr. med. vet. DipECVDI



HOSPITAL NAME

DPC Veterinary
Hospital

The information and recommendations provided are based on the images presented by the referring veterinarian/sonographer. No evaluation can be communicated regarding pathology that was not visible in the image/video clips provided.

Thank you for this referral. If the clinical or image interpretation does not parallel your findings or if I can be of any further assistance please contact me.

Sebastian Schaub, Sebastian Schaub, DVM, Dr. med. vet. DipECVDI
sebast.schaub@gmail.com

REFERRING VET

Dr. Feldt

INVOICE

54572

DATE

10-11-22