



PATIENT PRESENTING CLINICAL SIGNS

Toby Stewart History: Coughing after drinking

Abnormal PE/Chem/CBC/UA Results:

SPECIES

Canine

RADIOGRAPHIC STUDY OF THE THORAX

Radiographs of the thorax in three imaging planes are provided for review.

BREED

Bichon Frise

RADIOGRAPHIC FINDINGS

The surrounding bony structures are within normal limits.

SEX

Neutered Male

The extrathoracic soft tissues present homogeneous without abnormalities.

The heart is of normal size and shape, there is no evidence of cardiac chamber or vascular enlargement. The pulmonary vasculature is within normal limits.

AGE

8 Years

The cranial mediastinum presents the expected soft tissue opacity. The mediastinal width is less than twice the width of the vertebral column at the same level.

The trachea is normal in diameter and presents the anticipated course. The luminal outline of the trachea is smooth.

INTERPRETED BY

Sebastian Schaub,
DVM Dr. med. vet.
DipECVDI

A mild increased visibility of the bronchial walls is noted.

The lung parenchyma presents the expected architecture and opacity; the intrapulmonary vascular branching is seen up to the third order lung vessels.

HOSPITAL NAME

Rockaway AH

The diaphragm is well delineated with even surface and the expected mild cranial bulging of the diaphragmatic cupola.

RADIOGRAPHIC DIAGNOSIS

REFERRING VET

Dr. Maniar

- Very mild bronchial lung pattern

INTERPRETATION OF THE FINDINGS & FURTHER RECOMMENDATIONS

INVOICE

13673

The mild bronchial pattern is suggestive for mild bronchitis (e.g. allergic/inflammatory non-infectious versus infectious), if the finding explains the described clinical signs of cough after drinking is unclear when the patient is otherwise unremarkable. No additional abnormalities are appreciated.

DATE

10/11/21



PATIENT

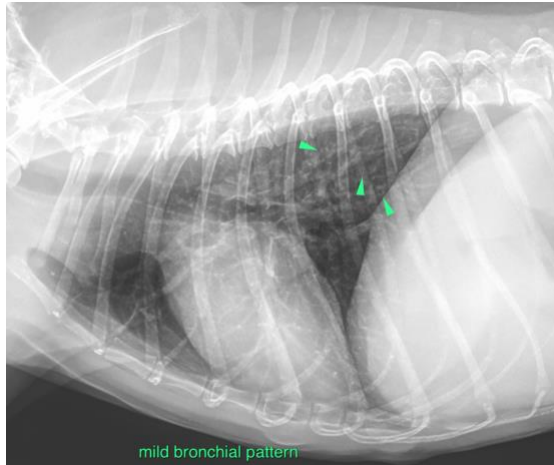
Toby Stewart

SPECIES

Canine

BREED

Bichon Frise



SEX

Neutered Male

The information and recommendations provided are based on the images presented by the referring veterinarian. No evaluation can be communicated regarding pathology that was not visible in the image/video clips provided.

AGE

8 Years

Thank you for this referral. If the clinical or image interpretation does not parallel your findings or if I can be of any further assistance please contact me.

Sebastian Schaub, Sebastian Schaub, DVM, Dr. med. vet. DipECVDI
sebast.schaub@gmail.com

INTERPRETED BY

Sebastian Schaub,
DVM Dr. med. vet.
DipECVDI

HOSPITAL NAME

Rockaway AH

REFERRING VET

Dr. Maniar

INVOICE

13673

DATE

10/11/21