



PATIENT

Orangie Norton

PRESENTING CLINICAL SIGNS

Neck soreness, sees acupuncturist

SPECIES

Feline

COMPUTED TOMOGRAPHY OF THE NECK

A high resolution plain CT study of the neck is provided for review.

BREED

Domestic Shorthair

COMPUTED TOMOGRAPHIC FINDINGS

The osseous and soft tissue structures of the neck are within normal limits.

COMPUTED TOMOGRAPHIC DIAGNOSIS

- Normal neck

SEX

Female Spayed

INTERPRETATION OF THE FINDINGS & FURTHER RECOMMENDATIONS

The CT study of the neck presents without abnormalities. If there is suspicion for underlying myelopathy, recommend complementing workup by a post contrast ± myelographic CT study or MRI study of the cervical spine.

AGE

8 Years, 8 Months

INTERPRETED BY

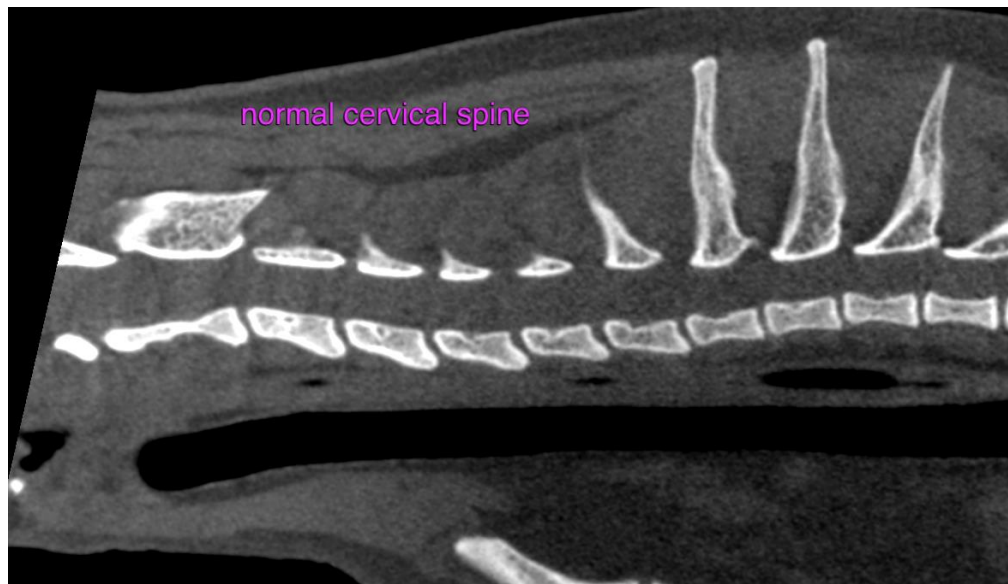
Sebastian Schaub, DVM
Dr. med. vet. DipECVDI

HOSPITAL NAME

Aggie Animal Dental
Center

REFERRING VET

Dr. Milinda Lommer



INVOICE

54545

The information and recommendations provided are based on the images presented by the referring veterinarian/sonographer. No evaluation can be communicated regarding pathology that was not visible in the image/video clips provided.

DATE

10-10-22

Thank you for this referral. If the clinical or image interpretation does not parallel your findings or if I can be of any further assistance please contact me.

Sebastian Schaub, Sebastian Schaub, DVM, Dr. med. vet. DipECVDI
sebast.schaub@gmail.com