



PATIENT PRESENTING CLINICAL SIGNS

Cookie Marien Chronic Right nasal/eye discharge

COMPUTED TOMOGRAPHY OF THE SKULL

SPECIES A high resolution pre- and post-contrast CT study of the skull is provided for review.

Feline **COMPUTED TOMOGRAPHIC FINDINGS**

BREED

All teeth but triadan 101-103, 202, 203, 204 (absent crown), 301-304, 401-404 and 408 are absent. Triadan 203 presents a transverse fracture within the alveolar crest. Advanced resorption of triadan 204 is appreciated – major parts of the crown are absent.

DSH In both nasal cavities, a moderate amount of fluid attenuating material is attached to the nasal mucosal lining. The nasal mucosal lining is moderately thickened.

SEX Both temporomandibular joints present congruent joint spaces with even subchondral bone surfaces and are considered within normal limits.

Female Spayed Both tympanic bullae are aerated, the mucosal lining is not seen, the bony wall is smooth and thin. The external ear canals are within normal limits.

AGE The brain presents no deviation from normal anatomy and symmetry. The brain parenchyma is homogeneous and within normal limits for attenuation and distribution of contrast enhancement. The ventricular system is non-dilated and symmetric.

13 Years, 6 Months

The medial retropharyngeal lymph nodes bilaterally are moderately enlarged, rounded and present a homogeneous contrast enhancement pattern.

INTERPRETED BY

Sebastian Schaub, DVM
Dr. med. vet. DipECVDI

Nodular enlargement of the left thyroid gland is visible, measuring 7 mm in diameter.

COMPUTED TOMOGRAPHIC DIAGNOSIS

HOSPITAL NAME

Mobile Pet Imaging
CFL

- Lymphadenopathy medial retropharyngeal lymph nodes
- Rhinitis
- Nodular enlargement left thyroid gland
- Advanced dental resorption 204
- Fractured triadan 203
- Multiple absent teeth

REFERRING VET

Meaux

INTERPRETATION OF THE FINDINGS & FURTHER RECOMMENDATIONS

The findings are consistent with chronic rhinitis. The most common cause is primary viral ± bacterial or less likely mycotic superinfection. The CT findings present without signs of biologically aggressive disease.

INVOICE

54531

Recommend rhinoscopy for further evaluation with sampling for culture and histopathology.

The enlarged medial retropharyngeal lymph nodes are equivocal for reactive hyperplasia or neoplastic transformation (e.g. lymphosarcoma). Recommend FNA sampling.

DATE

10-10-22

The prominent left thyroid gland is suggestive of (non)functional thyroid adenoma – correlate with findings from blood work.



PATIENT

Cookie Marien

SPECIES

Feline

BREED

DSH

SEX

Female Spayed

AGE

13 Years, 6 Months

INTERPRETED BY

Sebastian Schaub, DVM
Dr. med. vet. DipECVDI

HOSPITAL NAME

Mobile Pet Imaging
CFL

REFERRING VET

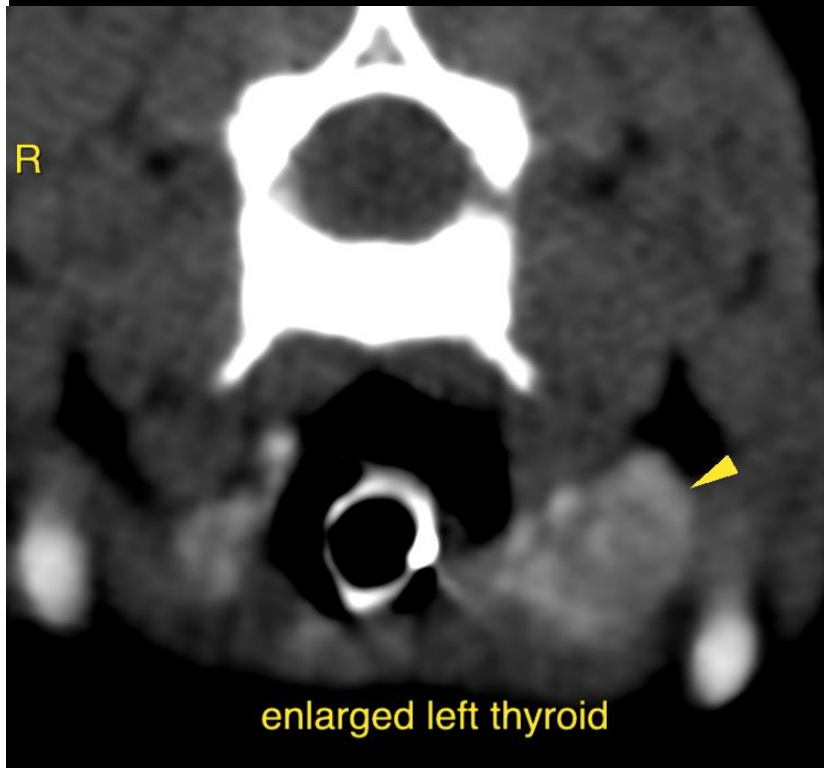
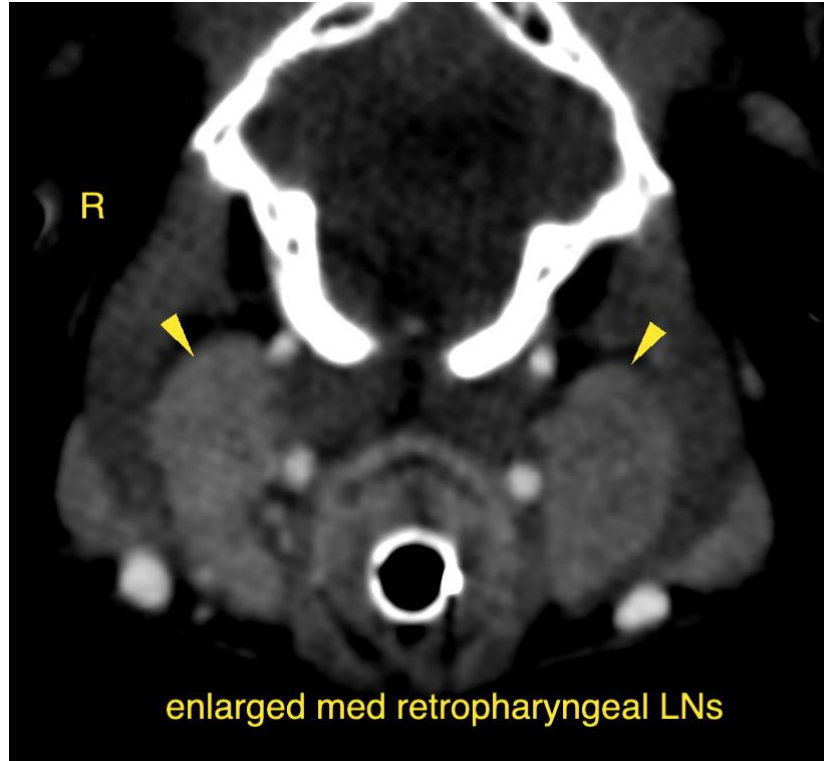
Meaux

INVOICE

54531

DATE

10-10-22





PATIENT

Cookie Marien

SPECIES

Feline

BREED

DSH

SEX

Female Spayed

AGE

13 Years, 6 Months

INTERPRETED BY

Sebastian Schaub, DVM
Dr. med. vet. DipECVDI

HOSPITAL NAME

Mobile Pet Imaging
CFL

REFERRING VET

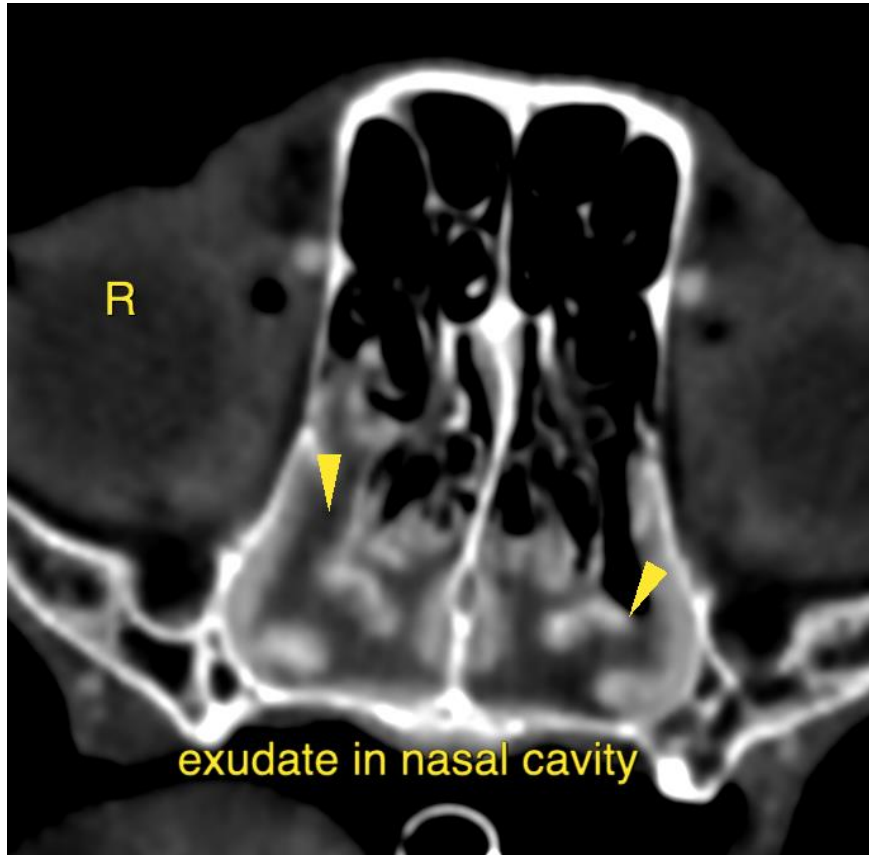
Meaux

INVOICE

54531

DATE

10-10-22



The information and recommendations provided are based on the images presented by the referring veterinarian/sonographer. No evaluation can be communicated regarding pathology that was not visible in the image/video clips provided.

Thank you for this referral. If the clinical or image interpretation does not parallel your findings or if I can be of any further assistance please contact me.

Sebastian Schaub, Sebastian Schaub, DVM, Dr. med. vet. DipECVDI
sebast.schaub@gmail.com