



PATIENT

Busy Hauck

PRESENTING CLINICAL SIGNS

of/on lameness on left hind for several months, noted limping on right front 10/3. O unsure if p injured herself.

SPECIES

Canine

Abnormal PE/Chem/CBC/UA Results: crepitus both elbows, no lameness noted on left hind on 10/3 pe - prior exam in December 21 p was toe touching, no appreciable drawer. Per o, seems to bother p more when running around more then normal.

RADIOGRAPHIC STUDY OF THE ELBOW & STIFLE JOINTS

A complete set of radiographs of the elbow and stifle joints is provided for review.

BREED

Hound Mix

RADIOGRAPHIC FINDINGS

The periarticular bones of both elbow joints present advanced osteophyte new bone formation. The contour of the medial coronoid process of both elbow joints cannot be defined.

SEX

SF

The periarticular bones of both stifle joints present mild osteophyte new bone formation. Both stifle joints present evidence of mild intracapsular soft tissue swelling, R>L, distorting the infrapatellar fat-pad. The patella bilaterally is in situ.

RADIOGRAPHIC DIAGNOSIS

AGE

2 Years

- Advanced degenerative osteoarthritis elbow joints bilaterally due to coronoid disease
- Mild degenerative osteoarthritis stifle joints bilaterally
- Mild articular swelling stifle joints bilaterally, R>L

INTERPRETED BY

Sebastian Schaub, DVM
Dr. med. vet. DipECVDI

INTERPRETATION OF THE FINDINGS & FURTHER RECOMMENDATIONS

The degenerative joint disease of both elbow joints is a sequela to underlying coronoid disease – CT study of the elbow joints might be used for further assessment of the elbow joints.

HOSPITAL NAME

The Pet Hospital of
Stratford

The radiographic study of the stifle joints is consistent with bilateral mild chronic degenerative osteoarthritis with concomitant joint effusion of both stifle joints. The most-likely underlying cause is (partial) rupture of the cranial cruciate ligament with or without meniscal disease.

A positive drawer sign or tibial compression test under general anesthesia can be used to confirm the diagnosis.

REFERRING VET

Dr. Giuliani

INVOICE

54529

DATE

10-10-22



PATIENT

Busy Hauck

SPECIES

Canine

BREED

Hound Mix

SEX

SF

AGE

2 Years

INTERPRETED BY

Sebastian Schaub, DVM
Dr. med. vet. DipECVDI

HOSPITAL NAME

The Pet Hospital of
Stratford

REFERRING VET

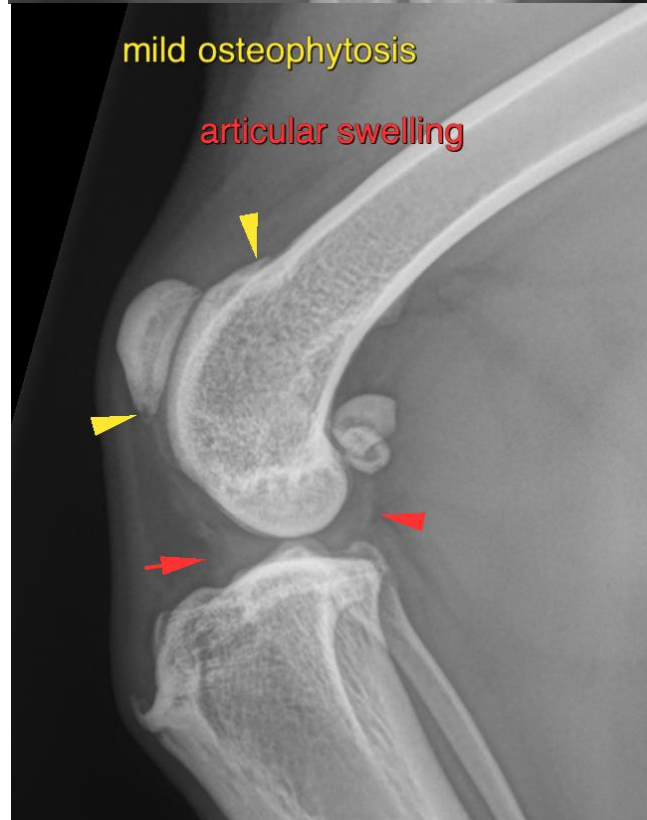
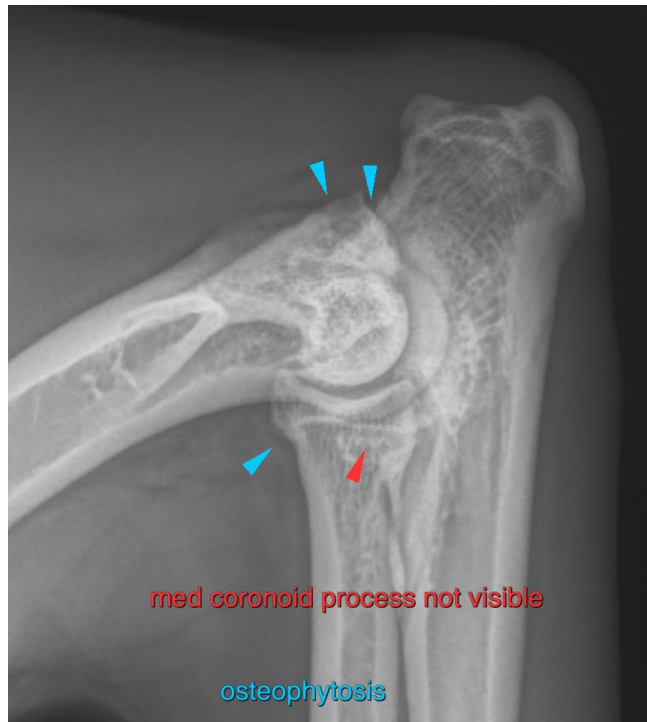Dr. Giuliani

INVOICE

54529

DATE

10-10-22





PATIENT

Busy Hauck

The information and recommendations provided are based on the images presented by the referring veterinarian/sonographer. No evaluation can be communicated regarding pathology that was not visible in the image/video clips provided.

Thank you for this referral. If the clinical or image interpretation does not parallel your findings or if I can be of any further assistance please contact me.

SPECIES

Canine

Sebastian Schaub, Sebastian Schaub, DVM, Dr. med. vet. DipECVDI
sebast.schaub@gmail.com

BREED

Hound Mix

SEX

SF

AGE

2 Years

INTERPRETED BY

Sebastian Schaub, DVM
Dr. med. vet. DipECVDI

HOSPITAL NAME

The Pet Hospital of
Stratford

REFERRING VET

Dr. Giuliani

INVOICE

54529

DATE

10-10-22