



PATIENT

Molly Vanerstein

PRESENTING CLINICAL SIGNS

Few months hx of progressive seizures. Discussed top ddx is intracranial disease (brain tumor, vascular event), however, cannot rule out other causes such as toxicity vs secondary to organ dysfunction vs other. Discussed options for referral to a neurologist vs overnight monitoring vs screening diagnostics and discharge with anticonvulsant. O elects to proceed with screening diagnostics and stabilization measures. Discussed potential for continued seizures and progression of signs if truly intracranial neoplasia; we also cannot rule out vascular event secondary to other type of neoplasia such as splenic mass, etc. Prognosis long term is very guarded. ASSESSMENT/Dx: Seizures, r/o intracranial neoplasia vs vascular event vs less likely toxicity vs other ALT elevation, r/o secondary to seizure vs primary hepatopathy

SPECIES

Canine

BREED

Lab Mix

COMPUTED TOMOGRAPHY OF THE SKULL & THORAX

A high resolution pre- and post-contrast CT study of the skull and a post-contrast CT study of the thorax are provided for review.

SEX

FS

COMPUTED TOMOGRAPHIC FINDINGS

Skull

The pictured parts of the dentition are complete and unremarkable in all jaw quadrants.

AGE

10 Years

The nasal cavity presents the expected aerated spaces between thin & even conchae and turbinates with smooth mucosal lining.

INTERPRETED BY

Sebastian Schaub, DVM
Dr. med. vet. DipECVDI

Both temporomandibular joints present congruent joint spaces with even subchondral bone surfaces and are considered within normal limits.

Both tympanic bullae are aerated, the mucosal lining is not seen, the bony wall is smooth and thin. The external ear canals present a mild to moderate thickening of the wall.

HOSPITAL NAME

Southern Oregon
Veterinary Specialty
Center

In the rostral cranial fossa, centered on the falx cerebri, an ill-defined mild contrast enhancing roundish mass is visible, measuring approximately 2.8 x 2.5 x 2.4 cm in size. Lateral deviation of the medial wall of the right orbit is seen by the mass effect in combination with pressure erosion of the bone.

The submandibular and medial retropharyngeal lymph nodes are small and elongated with a normal short-to-long-axis-ratio is < 0.5, the attenuation and contrast enhancement pattern is uniform.

REFERRING VET

Dr. Ravi Seshadri

Thorax

The vertebral endplates T5/T6 present moderate spondylosis formation. Mild enthesophyte formation is seen level with the insertion of the tendon of the supraspinatus muscle at the tuberculum majus of the humerus bilaterally.

INVOICE

54379

The sternal, cranial mediastinal and tracheobronchial lymph nodes are small elongated with a normal short-to-long-axis-ratio is < 0.5, the attenuation and contrast enhancement pattern is uniform and considered within normal limits.

DATE

10-1-22-

The cardiovascular structures including the pulmonary vasculature are within normal limits.



PATIENT

Molly Vanerstein

The bronchial tree presents with regular branching and tapers uniformly towards the periphery as expected, the bronchial walls are thin and smooth. The bronchus-to-artery ratio is within normal limits.

SPECIES

Canine

The lung parenchyma presents the expected architecture and attenuation behavior but regions of dystelectasis of the right cranioventral lung field.

Small incidental gas pockets are seen within the esophageal lumen, there is no evidence of abnormal dilation.

BREED

Lab Mix

COMPUTED TOMOGRAPHIC DIAGNOSIS

- Intracranial suspect extraaxial expansile mass rostral fossa cranii with pressure erosion medial wall right orbit
- Dystelectasis cranioventral aspects of the lung parenchyma, secondary to general anesthesia
- Spondylosis deformans
- Mild enthesophyte formation tendon supraspinatus muscle bilaterally
- No evidence of pulmonary metastatic disease

SEX

FS

INTERPRETATION OF THE FINDINGS & FURTHER RECOMMENDATIONS

The mass in the rostral cranial fossa appears to be extraaxial and meningioma or less likely esthesioneuroblastoma are considered as the top differentials in this location. If it is therapeutical relevant, the CT study can be complemented by an MRI study of the brain. The chances of radiation therapy can be discussed with oncologist.

AGE

10 Years

INTERPRETED BY

Sebastian Schaub, DVM
Dr. med. vet. DipECVDI

HOSPITAL NAME

Southern Oregon
Veterinary Specialty
Center

REFERRING VET

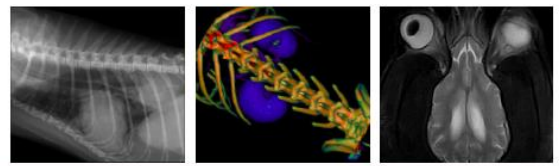
Dr. Ravi Seshadri

INVOICE

54379

DATE

10-1-22-



PATIENT

Molly Vanerstein

SPECIES

Canine

BREED

Lab Mix

SEX

FS

AGE

10 Years

INTERPRETED BY

Sebastian Schaub, DVM
Dr. med. vet. DipECVDI

HOSPITAL NAME

Southern Oregon
Veterinary Specialty
Center

REFERRING VET

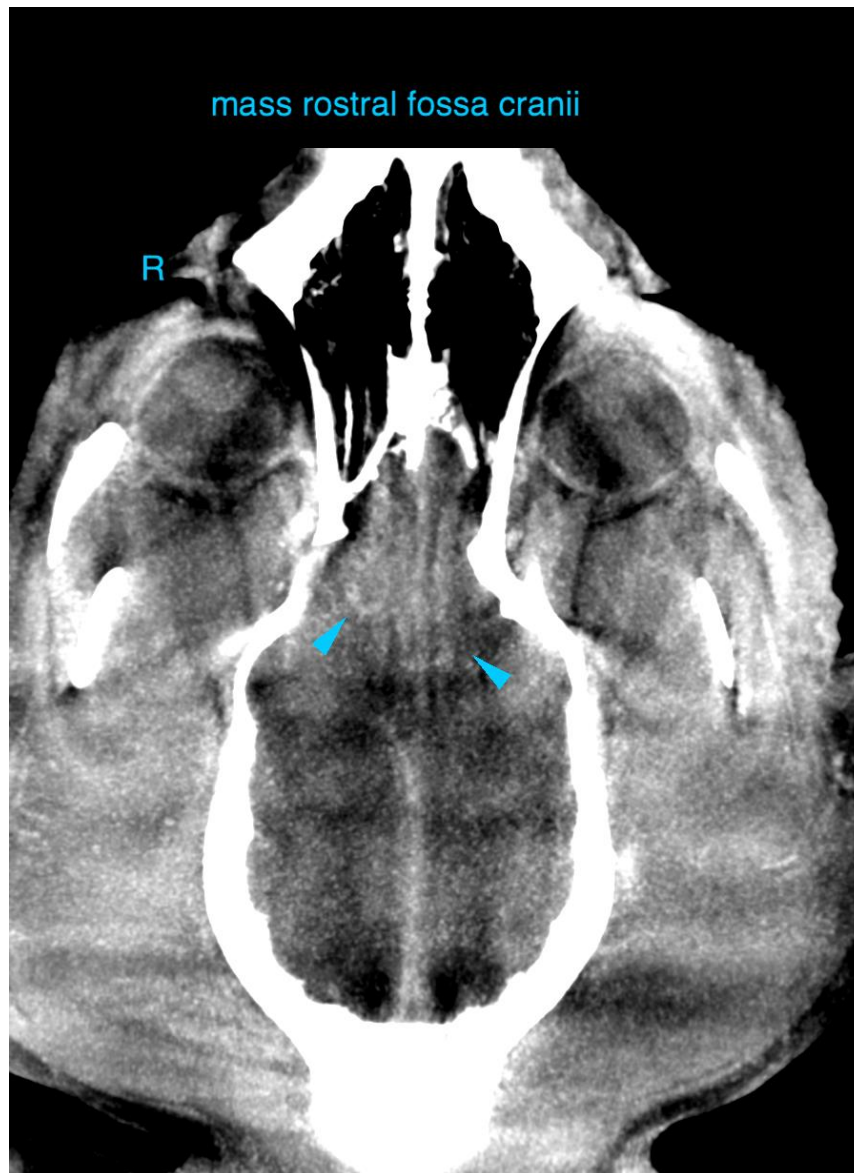
Dr. Ravi Seshadri

INVOICE

54379

DATE

10-1-22-





PATIENT

Molly Vanerstein

SPECIES

Canine

BREED

Lab Mix

SEX

FS

AGE

10 Years

INTERPRETED BY

Sebastian Schaub, DVM
Dr. med. vet. DipECVDI

HOSPITAL NAME

Southern Oregon
Veterinary Specialty
Center

REFERRING VET

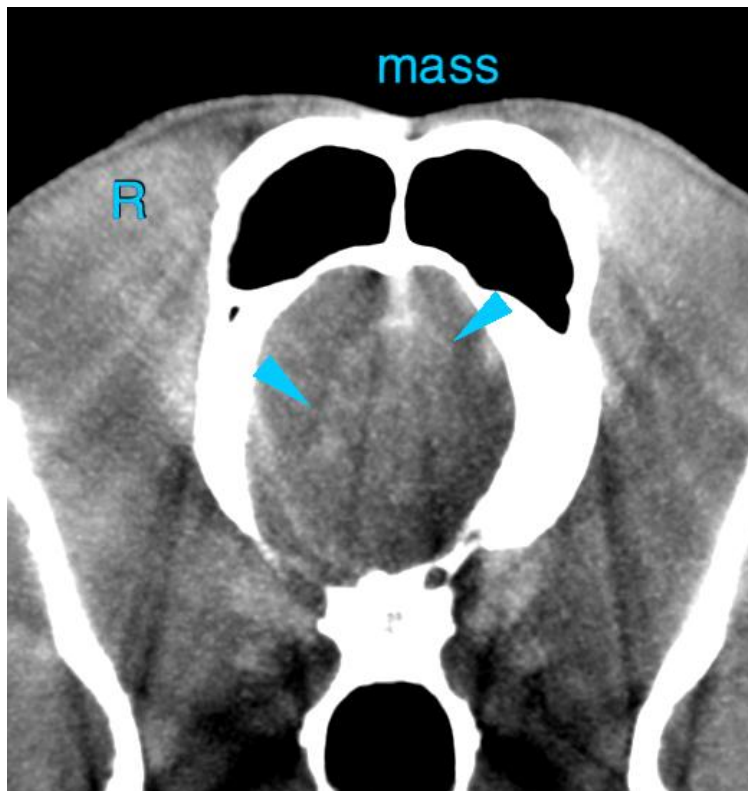
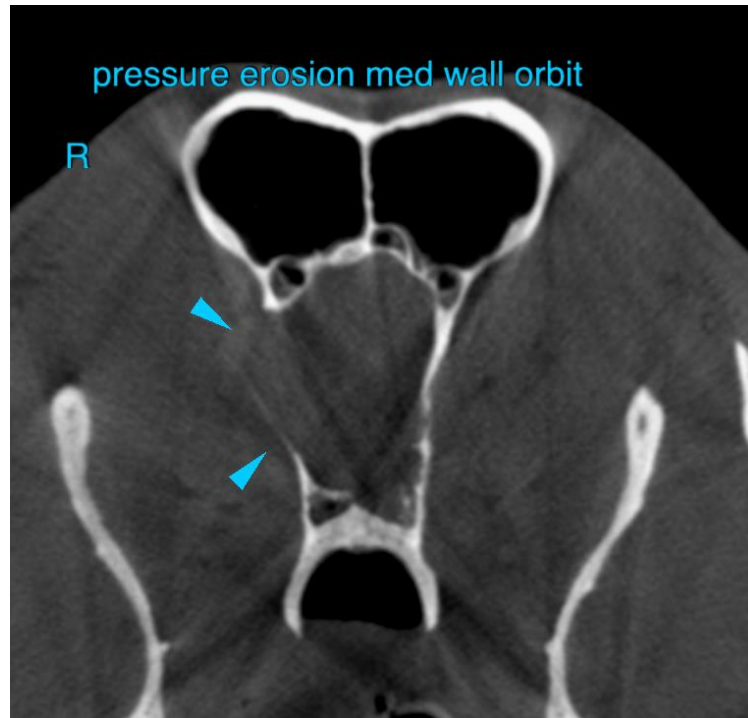
Dr. Ravi Seshadri

INVOICE

54379

DATE

10-1-22-





PATIENT

Molly Vanerstein

The information and recommendations provided are based on the images presented by the referring veterinarian/sonographer. No evaluation can be communicated regarding pathology that was not visible in the image/video clips provided.

Thank you for this referral. If the clinical or image interpretation does not parallel your findings or if I can be of any further assistance please contact me.

SPECIES

Canine

Sebastian Schaub, Sebastian Schaub, DVM, Dr. med. vet. DipECVDI
sebast.schaub@gmail.com

BREED

Lab Mix

SEX

FS

AGE

10 Years

INTERPRETED BY

Sebastian Schaub, DVM
Dr. med. vet. DipECVDI

HOSPITAL NAME

Southern Oregon
Veterinary Specialty
Center

REFERRING VET

Dr. Ravi Seshadri

INVOICE

54379

DATE

10-1-22-