



PATIENT PRESENTING CLINICAL SIGNS

Cami Fredrick History: 24 hour history of diarrhea, vomiting and anorexia. Hx of renal dz currently on 200 ml LRS EOD SQ.

SPECIES Abnormal PE/Chem/CBC/UA Results:SDMA 32, BUN 57 creat 2.2 in 07/2021. All else WNL. CBC/Chem/fecal/UA pending.

Canine

RADIOGRAPHIC STUDY OF THE ABDOMEN

BREED A full radiographic study of the abdomen is provided for revgiew.

Australian Shepherd

RADIOGRAPHIC FINDINGS

SEX The spine presents a generalized reduced density of the osseous structures. Multifocal moderate spondylosis formation is seen along the lumbar spine.

Spayed Female

No abnormalities of the extraabdominal soft tissues are noted. The abdominal wall is smooth and thin.

AGE

The serosal detail is maintained throughout the peritoneal and retroperitoneal space.

15 Years 7 Months

The hepatic volume is small and the gastric axis is deviated cranially.

The splenic head is in the anticipated position and within normal limits for size and opacity.

INTERPRETED BY

Sebastian Schaub,
DVM Dr. med. vet.
DipECVDI

Both kidneys are seen and present with normal size, shape, delineation and opacity. The urinary bladder is in its anticipated position. No radiopaque calculi are noted throughout the upper and lower urinary tract.

HOSPITAL NAME

Northvale VC

The stomach is in its anticipated position and contains a mild amount of gas and small mineralized body.

The small intestinal loops are of even diameter and non-dilated, a small amount of gas is seen within the small intestinal loops and considered within normal limits.

The colon is seen in the expected position and empty.

REFERRING VET

Dr. Stefanie Simon

The intrathoracic segment of the caudal vena cava presents a slender conformation and the pulmonary vessels are thin.

RADIOGRAPHIC DIAGNOSIS

INVOICE

13470

- Empty gastrointestinal tract
- Hypovolemia
- Mild microhepatica
- Generalized osteopenia

DATE

10/1/21



PATIENT • Spondylosis deformans

Cami Fredrick

INTERPRETATION OF THE FINDINGS & FURTHER RECOMMENDATIONS

SPECIES

Canine

The empty gastrointestinal tract in combination with the acute onset of clinical signs are suggestive for gastroenteritis. There is no evidence of radiopaque foreign material or signs for gastrointestinal mechanical obstruction. Empirical management is recommended.

BREED

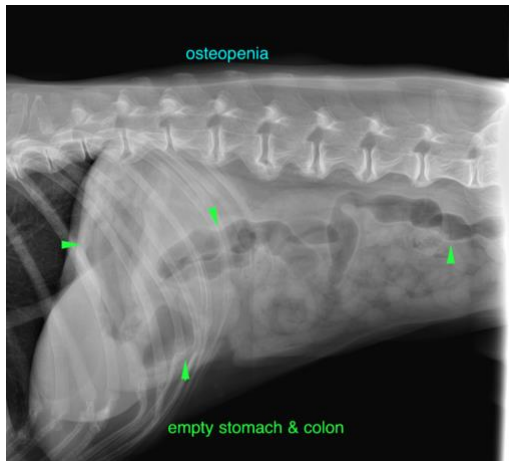
Australian Shepherd

SEX

Spayed Female

AGE

15 Years 7 Months



The mild microhepatic can present a normal anatomical variant or is a sequela to chronic hepatitis. The generalized osteopenia is likely a combination of the age of the patient and renal disease.

INTERPRETED BY

Sebastian Schaub,
DVM Dr. med. vet.
DipECVDI

The information and recommendations provided are based on the images presented by the referring veterinarian. No evaluation can be communicated regarding pathology that was not visible in the image/video clips provided.

HOSPITAL NAME

Northvale VC

Thank you for this referral. If the clinical or image interpretation does not parallel your findings or if I can be of any further assistance please contact me.

Sebastian Schaub, Sebastian Schaub, DVM, Dr. med. vet. DipECVDI
sebast.schaub@gmail.com

REFERRING VET

Dr. Stefanie Simon

INVOICE

13470

DATE

10/1/21