

PATIENT

Skippy Basile

SPECIES

Canine

BREED

Dachshund

SEX

Intact Male

AGE

11 Years 3 Months

WEIGHT

5.96 kg

INTERPRETED BY

Sebastian Schaub, DVM
Dr. med. vet. DipECVDI

IMAGING PERFORMED BY

Lisa S.

HOSPITAL NAME

ASC Oceanside

REFERRING VET

Dr. Infernuso

INVOICE

35359

DATE

1/9/26

PRESENTING CLINICAL SIGNS

History: non ambulatory in the HL, CP deficits, negative motor function Bilateral HL increased segmental reflexes painful in TL region T3-L3 myelopathy.

COMPUTED TOMOGRAPHIC STUDY OF THE THORACIC AND LUMBAR SPINE

A high resolution plain and myelographic CT study of the thoracic and lumbar spine is provided for review.

COMPUTED TOMOGRAPHIC FINDINGS

THE LAST RIB BEARING VERTEBRA IS COUNTED AS T13.

Multiple intervertebral discs along the thoracic and lumbar spine present variable degree of central mineralization.

The remainder of the osseous and soft tissue structures of the thoracic spine reveal no abnormalities.

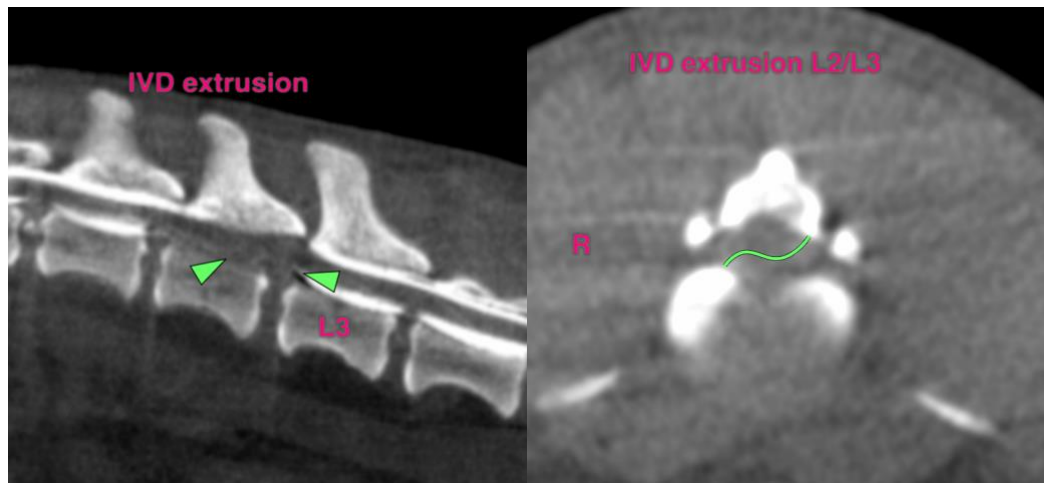
Level with the intervertebral disc space L2/L3, in the left lateroventral aspect of the vertebral canal heterogeneous mineral attenuating material is seen occupying approximately up to 40% of the cross-sectional area of the vertebral canal at the same level. Post intrathecal contrast administration the spinal cord level L2/L3 is deviated dorsally and to the left and is distorted. The extradural material is extending cranially up to the level of the mid third of the vertebral body L2.

COMPUTED TOMOGRAPHIC DIAGNOSIS

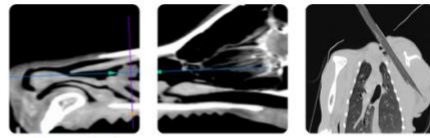
- Left sided intervertebral disc extrusion L2/L3 with compressive myelopathy
- Multifocal chondroid disc degeneration along the thoracic and lumbar spine

INTERPRETATION OF THE FINDINGS & FURTHER RECOMMENDATIONS

The intervertebral disc extrusion L2/L3 is a plausible explanation for the presenting clinical signs and surgical decompression is beneficial.



The information and recommendations provided are based on the images presented by the referring veterinarian/sonographer. No evaluation can be communicated regarding pathology



PATIENT

Skippy Basile

SPECIES

Canine

BREED

Dachshund

SEX

Intact Male

AGE

11 Years 3 Months

WEIGHT

5.96 kg

INTERPRETED BY

Sebastian Schaub, DVM
Dr. med. vet. DipECVDI

**IMAGING
PERFORMED BY**

Lisa S.

HOSPITAL NAME

ASC Oceanside

REFERRING VET

Dr. Infernuso

INVOICE

35359

DATE

1/9/26

that was not visible in the image/video clips provided.

Thank you for this referral. If the clinical or image interpretation does not parallel your findings or if I can be of any further assistance please contact me.

Sebastian Schaub, DVM, Dr. med. vet. DipECVDI

info@sonopath.com