



**PATIENT**

Wally Maxwell

**PRESENTING CLINICAL SIGNS**

History of seizure yesterday night. There is radio opaque stuff either in the pylorus, could be from the raw food and could be from the gall bladder.  
Abnormal PE/Chem/CBC/UA Results: Blood work within normal limit.

**SPECIES**

Canine

**RADIOGRAPHIC STUDY OF THE ABDOMEN**

Radiographs of the abdomen in three imaging planes are provided for review.

**BREED**

French Bulldog

**RADIOGRAPHIC FINDINGS**

The intervertebral disc space T13/L1 is moderately narrowed. The vertebral endplates L3/L4 and L7/S1 present ventral spondylosis formation.

No abnormalities of the extraabdominal soft tissues are noted. The abdominal wall is smooth and thin.

**SEX**

Neutered Male

The serosal detail is maintained throughout the peritoneal and retroperitoneal space.

The liver is appropriate in position, size and presents uniform opacity.

**AGE**

10 Years

The splenic head is in the anticipated position and within normal limits for size and opacity. The splenic body and tail are considered normal for position, size, shape and opacity.

Both kidneys are seen and present with normal size, shape, delineation and opacity. The urinary bladder is in its anticipated position. No radiopaque calculi are noted throughout the upper and lower urinary tract.

**INTERPRETED BY**

Sebastian Schaub, DVM  
Dr. med. vet. DipECVDI

The stomach is in its anticipated position and contains heterogeneous soft tissue and gas opaque material. Mineral opaque granular material is seen in the pyloric region of the stomach.

The duodenum is distended by gas and appears adynamic. The small intestinal loops are mildly dilated and contain foamy soft tissue material.

**HOSPITAL NAME**

Truscott Animal  
Hospital

The colon is seen in the expected position and presents with appropriate content.

**RADIOGRAPHIC DIAGNOSIS**

**REFERRING VET**

Dr. Medhat Meawad

- Chymus throughout the gastrointestinal tract
- Mineralized material in stomach
- Discopathy T13/L1
- Spondylosis deformans

**INVOICE**

56050

**INTERPRETATION OF THE FINDINGS & FURTHER RECOMMENDATIONS**

The mineralized material is located in the pyloric region of the stomach and is considered as a sequela to the history of the raw food. The pattern of the gastrointestinal tract is suggestive for preceding food intake, resulting in the alimentary pattern. There is no evidence of gastrointestinal mechanical obstruction.

**DATE**

1-9-23

The adynamic appearing duodenum might can be an incidental finding, as there is no history of vomiting, but can be a sign for pancreatitis.



**PATIENT**

Wally Maxwell

**SPECIES**

Canine

**BREED**

French Bulldog

**SEX**

Neutered Male

**AGE**

10 Years

**INTERPRETED BY**

Sebastian Schaub, DVM  
Dr. med. vet. DipECVDI

**HOSPITAL NAME**

Truscott Animal  
Hospital

**REFERRING VET**

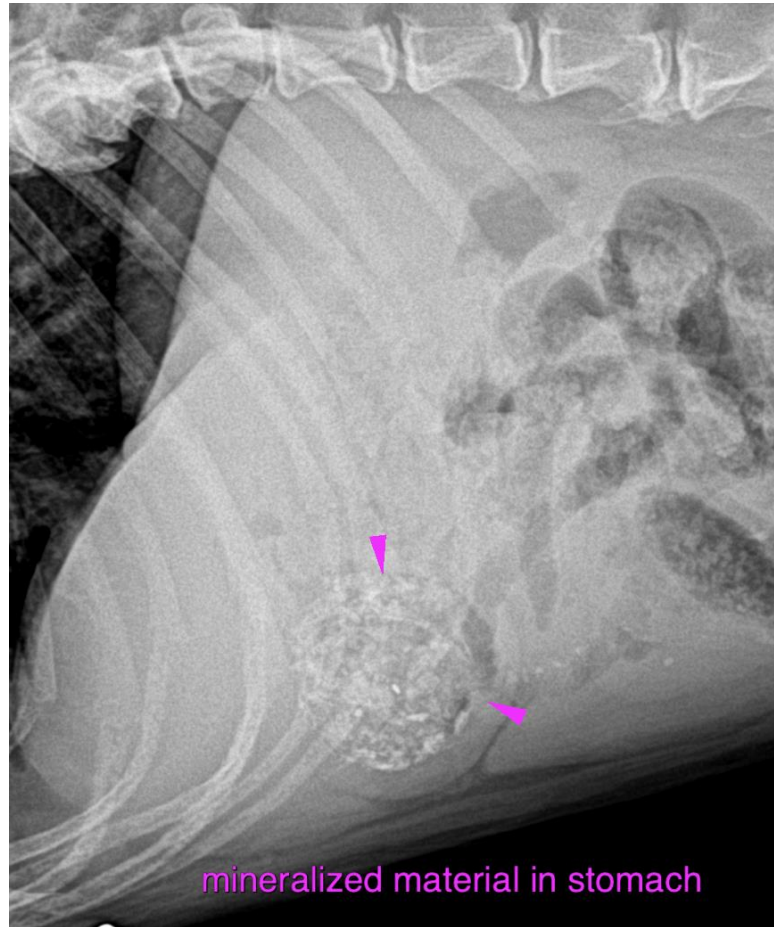
Dr. Medhat Meawad

**INVOICE**

56050

**DATE**

1-9-23



The information and recommendations provided are based on the images presented by the referring veterinarian/sonographer. No evaluation can be communicated regarding pathology that was not visible in the image/video clips provided.

Thank you for this referral. If the clinical or image interpretation does not parallel your findings or if I can be of any further assistance please contact me.

**Sebastian Schaub**, Sebastian Schaub, DVM, Dr. med. vet. DipECVDI  
sebast.schaub@gmail.com