



**PATIENT**

Bailey Rose Erdos

**SPECIES**

Canine

**BREED**

Yorkie

**SEX**

SF

**AGE**

13.5 Years

**INTERPRETED BY**

Sebastian Schaub, DVM  
Dr. med. vet. DipECVDI

**HOSPITAL NAME**

The Pet Hospital of  
Stratford

**REFERRING VET**

Dr. Giuliani

**INVOICE**

56053

**DATE**

1-9-23

**PRESENTING CLINICAL SIGNS**

Pt presented for vomiting and diarrhea that started about 3-4 days ago. The first time pt vomited it looked like a hairball and grass. Pt not holding down food but is holding water. Pt having liquid diarrhea, but o not seeing any blood. O doesn't think pt got into anything. PE: moderate dehydration, 3.5lb weight loss since 10/22. BW/UA/CPL pending.  
Abnormal PE/Chem/CBC/UA Results:

**RADIOGRAPHIC STUDY OF THE ABDOMEN**

Radiographs of the abdomen in three imaging planes are provided for review.

**RADIOGRAPHIC FINDINGS**

The surrounding bony structures are within normal limits.

No abnormalities of the extraabdominal soft tissues are noted. The abdominal wall is smooth and thin.

The serosal detail is maintained throughout the peritoneal and retroperitoneal space.

The liver is appropriate in position, size and presents uniform opacity.

The splenic head is in the anticipated position and within normal limits for size and opacity. The splenic body and tail are considered normal for position, size, shape and opacity.

Both kidneys are seen and present with normal size, shape, delineation and opacity. A small amount of mineral opaque material is seen in the imaging plane of the renal pelvis bilaterally. The urinary bladder is in its anticipated position. No radiopaque calculi are noted throughout the lower urinary tract.

The stomach is in its anticipated position and is empty. In the right cranial abdomen, a linear, metal opaque body is seen, measuring 2 cm in length

The small intestinal loops are generalized mildly dilated by fluid and a small amount of gas.

The colon is seen in the expected position and is empty but a moderate amount of gas. The colon is mildly undulating.

**RADIOGRAPHIC DIAGNOSIS**

- Empty gastrointestinal tract
- Rigid appearing and mildly fluid distended small intestinal loops
- Migrating foreign (wire) body right cranial abdomen
- Nephrolithiasis

**INTERPRETATION OF THE FINDINGS & FURTHER RECOMMENDATIONS**

The overall empty gastrointestinal tract, mild fluid filled small intestinal loops and empty colon in combination with the presenting clinical signs are suggestive for gastroenteritis with possible secondary functional ileus. If not done so yet, recommend complementing lab work by cpl to screen for underlying pancreatitis. There is no evidence signs for gastrointestinal mechanical obstruction. If clinical signs are refractory to therapy, recommend follow up radiographs or a complete abdominal ultrasound examination.

The small wire in the right cranial abdomen is commonly an incidental finding and not associated



**PATIENT**

with clinical signs.

Bailey Rose Erdos

**SPECIES**

Canine

**BREED**

Yorkie

**SEX**

SF

**AGE**

13.5 Years

**INTERPRETED BY**

Sebastian Schaub, DVM  
Dr. med. vet. DipECVDI

**HOSPITAL NAME**

The Pet Hospital of  
Stratford

**REFERRING VET**

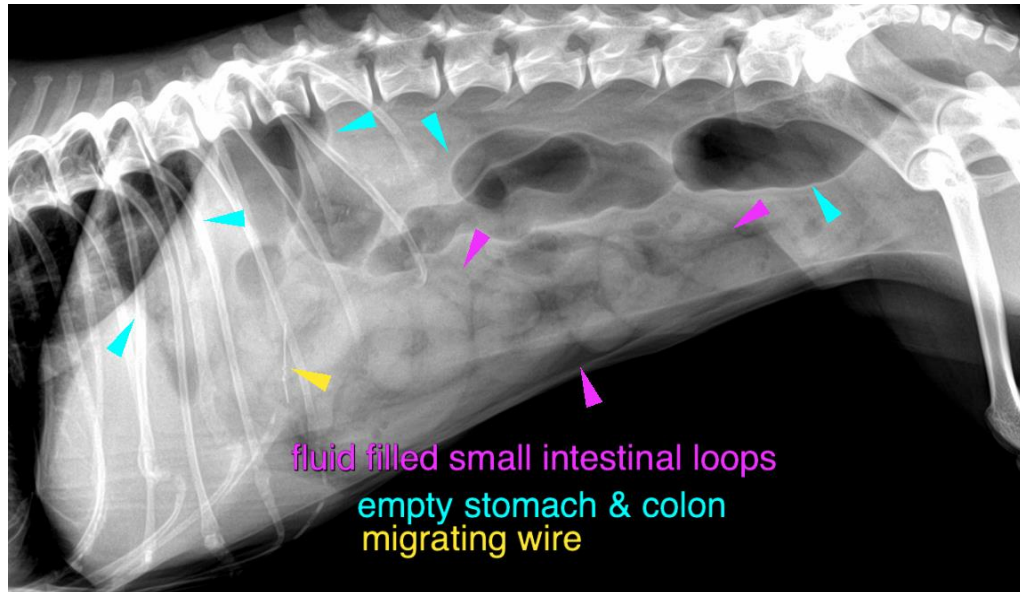
Dr. Giuliani

**INVOICE**

56053

**DATE**

1-9-23



The information and recommendations provided are based on the images presented by the referring veterinarian/sonographer. No evaluation can be communicated regarding pathology that was not visible in the image/video clips provided.

Thank you for this referral. If the clinical or image interpretation does not parallel your findings or if I can be of any further assistance please contact me.

**Sebastian Schaub**, Sebastian Schaub, DVM, Dr. med. vet. DipECVDI  
sebast.schaub@gmail.com