



PATIENT

Scooby Waitt

SPECIES

Feline

BREED

Balinese

SEX

FS

AGE

4

WEIGHT

4.06kg

INTERPRETED BY

Sebastian Schaub, DVM
Dr. med. vet.
DipECVDI

IMAGING PERFORMED BY

LL & JL

HOSPITAL NAME

My Pet Mobile Vet

REFERRING VET

Dr. Ren Garcia

INVOICE

73261

DATE

1-8-26

PRESENTING CLINICAL SIGNS

Testing heartworm positive since 12/18/2025. No clinical concerns noted at home. Abnormal PE/Chem/CBC/UA Results: 12/18/2025: Heartworm Antigen by ELISA - Positive; Heartworm Antibody by ELISA- Negative. 12/24/2025: Heartworm Antibody by ELISA- Negative; Heartworm Antigen by ELISA - No Heat - Positive; Heartworm Antigen with Heat Treatment (ELISA)- Negative. Was seen by cardiologist today (1/8/2026) who did not see any obvious signs of heartworm on echocardiogram. No obvious signs of heartworm on chest radiographs performed today (1/8/2026).

RADIOGRAPHIC STUDY OF THE THORAX

Radiographs of the thorax in three imaging planes are provided for review.

RADIOGRAPHIC FINDINGS

The surrounding bony structures are within normal limits.

The extrathoracic soft tissues present homogeneous without abnormalities.

The cardiac silhouette is elongated and has a slender conformation in the lateral views. No abnormalities of the cardiac silhouette in the VD view are seen. The pulmonary vasculature is within normal limits.

The trachea is normal in diameter and presents the anticipated course. The luminal outline of the trachea is smooth.

The bronchial tree presents with thin walls and tapers uniformly towards the periphery as expected.

The lung parenchyma presents the expected architecture and opacity; the intrapulmonary vascular branching is seen up to the third order lung vessels.

The diaphragm is well delineated with even surface and the expected mild cranial bulging of the diaphragmatic cupola.

RADIOGRAPHIC DIAGNOSIS

- Equivocal mild cardiomegaly
- Normal lower airways

INTERPRETATION OF THE FINDINGS & FURTHER RECOMMENDATIONS

The alteration of the appearance of the cardiac silhouette is most likely an anatomical variant, however, to rule out cardiomyopathy entirely, workup can be complemented by a cardiac echo.



PATIENT

Scooby Waitt

SPECIES

Feline

BREED

Balinese

SEX

FS

AGE

4

WEIGHT

4.06kg

INTERPRETED BY

Sebastian Schaub, DVM
Dr. med. vet.
DipECVDI

IMAGING PERFORMED BY

LL & JL

HOSPITAL NAME

My Pet Mobile Vet

REFERRING VET

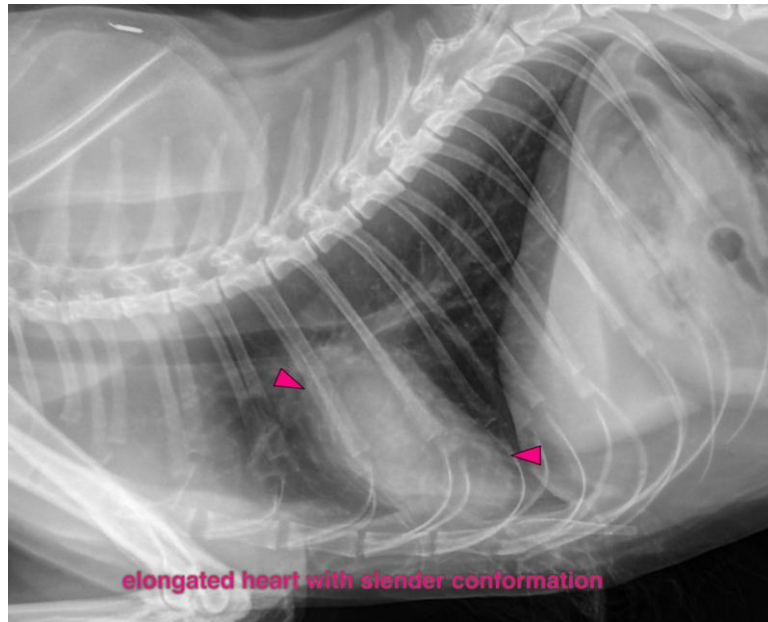
Dr. Ren Garcia

INVOICE

73261

DATE

1-8-26



The information and recommendations provided are based on the images presented by the referring veterinarian/sonographer. No evaluation can be communicated regarding pathology that was not visible in the image/video clips provided.

Thank you for this referral. If the clinical or image interpretation does not parallel your findings or if I can be of any further assistance please contact me.

Sebastian Schaub, Sebastian Schaub, DVM, Dr. med. vet. DipECVDI
info@sonopath.com