



## PATIENT

Miles Kor

## SPECIES

Canine

## BREED

Morkie

## SEX

MN

## AGE

6Y, 7M

## WEIGHT

14.8

## INTERPRETED BY

Sebastian Schaub, DVM  
Dr. med. vet.  
DipECVDI

## IMAGING PERFORMED BY

Shannon Vasiliauskas,  
CVT

## HOSPITAL NAME

Pocono Peak  
Veterinary Center

## REFERRING VET

Dr. Christine Coyle

## INVOICE

73253

## DATE

1-8-26

## PRESENTING CLINICAL SIGNS

P presented 12/22/25 for acute onset non-weight bearing lameness of left front leg. Radiograph done. Dispensed Carprofen. O reported no improvements 12/24, added in Gabapentin for a week. O stated still not seeing any improvement. Completed sedated radiographs today. P is limping but no improvement since 12/29.

## RADIOGRAPHIC STUDY OF THE LEFT ELBOW JOINT

Radiographs of the left elbow joint in orthogonal image planes are provided for review.

## RADIOGRAPHIC FINDINGS

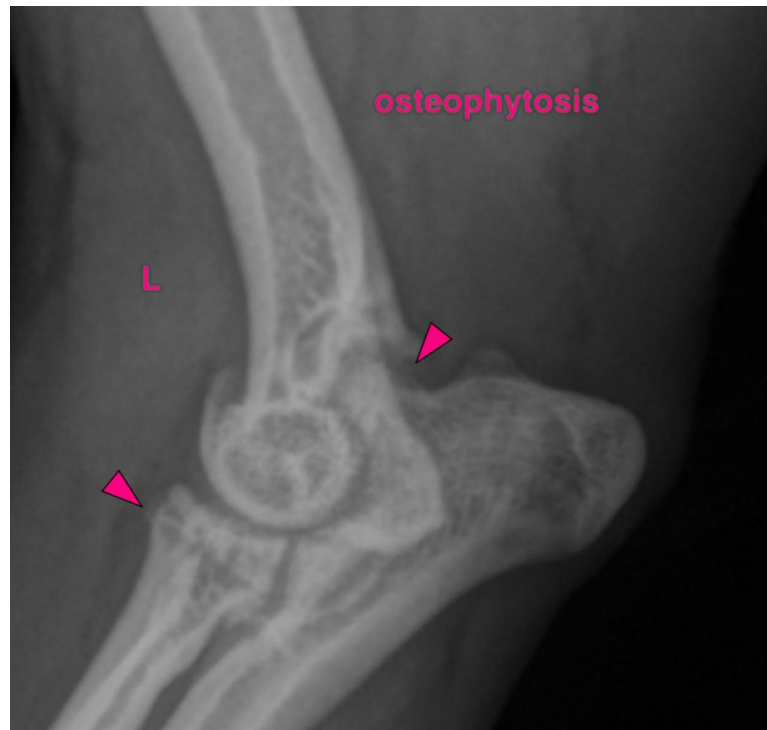
The periarticular bones of the left elbow joint present mild to moderate osteophyte new bone formation. The surrounding soft tissue structures of the left elbow joint are within normal limits.

## RADIOGRAPHIC DIAGNOSIS

- Osteoarthritis left elbow joint

## INTERPRETATION OF THE FINDINGS & FURTHER RECOMMENDATIONS

The radiographic study presents degenerative joint disease of the left elbow joint – an acute exacerbation of a chronic condition may have contributed to the recent development of clinical signs. However, as the clinical signs are refractory to empirical therapy, rule out pathology of the cervical spine brachial plexus region, distal aspects of the front limb or soft tissue pathologies as well.





**PATIENT**

Miles Kor

The information and recommendations provided are based on the images presented by the referring veterinarian/sonographer. No evaluation can be communicated regarding pathology that was not visible in the image/video clips provided.

**SPECIES**

Canine

Thank you for this referral. If the clinical or image interpretation does not parallel your findings or if I can be of any further assistance please contact me.

**BREED**

Morkie

**Sebastian Schaub**, Sebastian Schaub, DVM, Dr. med. vet. DipECVDI

[info@sonopath.com](mailto:info@sonopath.com)

**SEX**

MN

**AGE**

6Y, 7M

**WEIGHT**

14.8

**INTERPRETED BY**

Sebastian Schaub, DVM  
Dr. med. vet.  
DipECVDI

**IMAGING  
PERFORMED BY**

Shannon Vasiliauskas,  
CVT

**HOSPITAL NAME**

Pocono Peak  
Veterinary Center

**REFERRING VET**

Dr. Christine Coyle

**INVOICE**

73253

**DATE**

1-8-26