



PATIENT

Holly Reposa

SPECIES

Canine

BREED

Yorkie

SEX

FS

AGE

12Y

WEIGHT

6.9lbs

INTERPRETED BY

Sebastian Schaub, DVM
Dr. med. vet. DipECVDI

IMAGING PERFORMED BY

Mobile Pet Imaging

HOSPITAL NAME

Mobile Pet Imaging

REFERRING VET

Armstrong

INVOICE

73256

DATE

1-8-26

PRESENTING CLINICAL SIGNS

Pet has a possible left adrenal gland mass.

COMPUTED TOMOGRAPHY OF THE THORAX AND ABDOMEN

A high resolution pre- and post-contrast CT study of the thorax and abdomen is provided for review.

COMPUTED TOMOGRAPHIC FINDINGS

Thorax

The intervertebral disc space C6/C7 is collapsed, and the respective vertebral endplates present moderate spondylosis formation. Level with the intervertebral disc space C6/C7, irregular mild mineralized material is protruding into the vertebral canal, occupying approximately <10% of the cross-sectional area of the vertebral canal at the same level.

The periarticular bones of both shoulder joints present moderate osteophyte new bone formation.

The sternal, cranial mediastinal and tracheobronchial lymph nodes are small elongated with a normal short-to-long-axis-ratio is < 0.5, the attenuation and contrast enhancement pattern is uniform and considered within normal limits.

The cardiovascular structures including the pulmonary vasculature are within normal limits.

The bronchial tree presents with regular branching and tapers uniformly towards the periphery as expected, the bronchial walls are thin and smooth. The bronchus-to-artery ratio is within normal limits.

The lung parenchyma presents the expected architecture and attenuation behavior.

Small incidental gas pockets are seen within the esophageal lumen; there is no evidence of abnormal dilation.

Abdomen

The serosal fat presents normal attenuation behavior. There is no evidence of peritoneal effusion or peritonitis.

Both kidneys present within normal limits for size, shape and organ architecture. After contrast administration, a bilaterally symmetric and uniform nephro- and pyelogram is noted.

Originating from the left adrenal gland, an ovoid shaped, uniform soft tissue attenuating and heterogeneous contrast enhancing mass is seen; measuring 1.6 cm in diameter and 21 mm in length.

Both liver and spleen present with normal shape, even surface, uniformly attenuating parenchyma. The liver has a homogeneous contrast enhancement pattern. The spleen presents a mild irregular contrast uptake - with mild hyperattenuating intraparenchymal nodular lesions.

The pancreas is evenly contoured; the pancreatic parenchyma is homogeneous and presents uniform contrast enhancement.

The position, delineation, wall and content of the gastrointestinal tract are considered within normal limits throughout.

Along the thoracolumbar junction multifocal spondylosis formation is seen and multiple intervertebral disc are protruding into the vertebral canal, occupying approximately ≤15% of the cross-sectional area of the vertebral canal at the same level.



PATIENT

Holly Reposa

SPECIES

Canine

BREED

Yorkie

SEX

FS

AGE

12Y

WEIGHT

6.9lbs

INTERPRETED BY

Sebastian Schaub, DVM
Dr. med. vet. DipECVDI

IMAGING PERFORMED BY

Mobile Pet Imaging

HOSPITAL NAME

Mobile Pet Imaging

REFERRING VET

Armstrong

INVOICE

73256

DATE

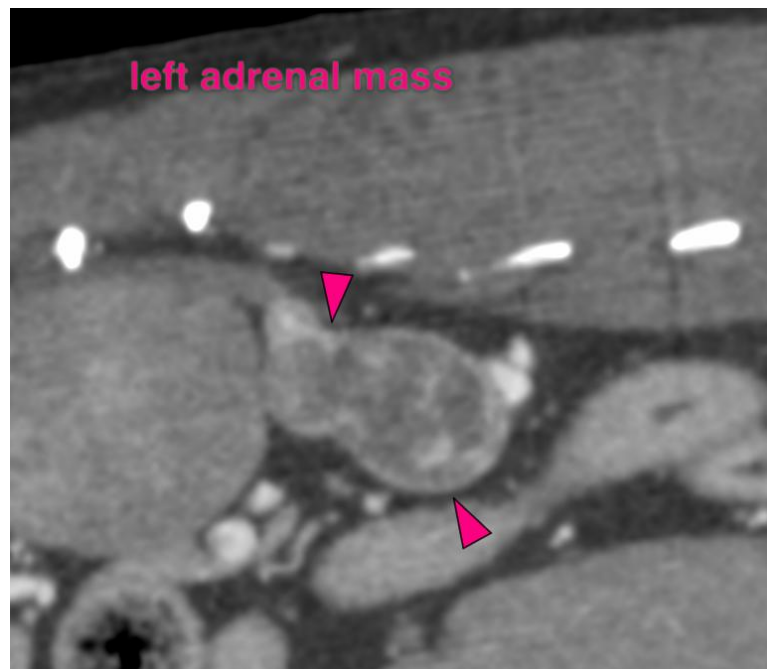
1-8-26

COMPUTED TOMOGRAPHIC DIAGNOSIS

- Left adrenal soft tissue mass without vascular invasion
- Chronic discopathy C6/C7 and multifocal along the thoracolumbar junction with dynamic myelopathy and chronic osseous remodeling of the respective vertebral endplates
- Mild hyperattenuating intraparenchymal splenic nodular areas – suggestive for nodular hyperplasia versus extramedullary hematopoiesis
- Spondylosis deformans
- No evidence of pulmonary metastatic disease

INTERPRETATION OF THE FINDINGS & FURTHER RECOMMENDATIONS

The CT study is confirm the presence of a left adrenal soft tissue mass, consistent with (non)functional adrenal neoplasia (e.g. adenocarcinoma, pheochromocytoma). Completes surgical resection of the left adrenal mass is considered feasible.



The information and recommendations provided are based on the images presented by the referring veterinarian/sonographer. No evaluation can be communicated regarding pathology that was not visible in the image/video clips provided.

Thank you for this referral. If the clinical or image interpretation does not parallel your findings or if I can be of any further assistance please contact me.

Sebastian Schaub, Sebastian Schaub, DVM, Dr. med. vet. DipECVDI
info@sonopath.com