



PATIENT

Daisy Odencrantz

PRESENTING CLINICAL SIGNS

stomped on by moose. Difficulty walking in hind end
Abnormal PE/Chem/CBC/UA Results: No obvious signs of fracture or pain on exam. Slightly ataxic in hind. Neuro normal.

SPECIES

Canine

RADIOGRAPHIC STUDY OF THE THORAX & ABDOMEN

A complete set of radiographs of the thorax and abdomen is provided for review.

BREED

CKCS

RADIOGRAPHIC FINDINGS

Thorax

The surrounding bony structures are within normal limits.

SEX

FS

The extrathoracic soft tissues present homogeneous without abnormalities.

The heart is of normal size and shape, there is no evidence of cardiac chamber or vascular enlargement. The vertebral heart score is 10.3 The pulmonary vasculature is within normal limits.

AGE

6 Years

The cranial mediastinum presents the expected soft tissue opacity. The mediastinal width is less than twice the width of the vertebral column at the same level.

INTERPRETED BY

Sebastian Schaub, DVM
Dr. med. vet. DipECVDI

The trachea is normal in diameter and presents the anticipated course. The luminal outline of the trachea is smooth.

The bronchial tree presents with thin walls and tapers uniformly towards the periphery as expected.

HOSPITAL NAME

Pinebrook Animal
Hospital

The lung parenchyma presents the expected architecture and opacity; the intrapulmonary vascular branching is seen up to the third order lung vessels.

The diaphragm is well delineated with even surface and the expected mild cranial bulging of the diaphragmatic cupola.

REFERRING VET

Dr. Britt Dubil

Abdomen

The vertebral endplates L2/L3 present moderate spondylosis formation.

No abnormalities of the extraabdominal soft tissues are noted. The abdominal wall is smooth and thin.

INVOICE

49407

The serosal detail is maintained throughout the peritoneal and retroperitoneal space.

The liver is appropriate in position, size and presents uniform opacity.

DATE

1-8-22

The splenic head is in the anticipated position and within normal limits for size and opacity. The splenic body and tail are considered normal for position, size, shape and opacity.

Both kidneys are seen and present with normal size, shape, delineation and opacity. The urinary



PATIENT

Daisy Odencrantz

bladder is in its anticipated position and mildly distended. No radiopaque calculi are noted throughout the upper and lower urinary tract.

The stomach is in its anticipated position and contains a mild to moderate amount of ingesta with granular mineralized material in the pyloric region.

SPECIES

Canine

The small intestinal loops are of even diameter and non-dilated, a small amount of gas is seen within the small intestinal loops and considered within normal limits.

The colon is seen in the expected position and presents with appropriate content.

BREED

CKCS

RADIOGRAPHIC DIAGNOSIS

- Spondylosis L2/L3
- Normal thorax

SEX

FS

INTERPRETATION OF THE FINDINGS & FURTHER RECOMMENDATIONS

The radiographic study of the thorax and abdomen presents without clinically relevant pathology. Acute on chronic disc disease might be a potential here – if clinical signs are refractory to empirical management cross-sectional imaging can be used as advanced diagnostic tool.

AGE

6 Years

There are no signs for cardiac enlargement.

INTERPRETED BY

Sebastian Schaub, DVM
Dr. med. vet. DipECVDI

HOSPITAL NAME

Pinebrook Animal
Hospital

REFERRING VET

Dr. Britt Dubil

INVOICE

49407

DATE

1-8-22



PATIENT

Daisy Odenchantz

SPECIES

Canine

BREED

CKCS

SEX

FS

AGE

6 Years

INTERPRETED BY

Sebastian Schaub, DVM
Dr. med. vet. DipECVDI

HOSPITAL NAME

Pinebrook Animal
Hospital

REFERRING VET

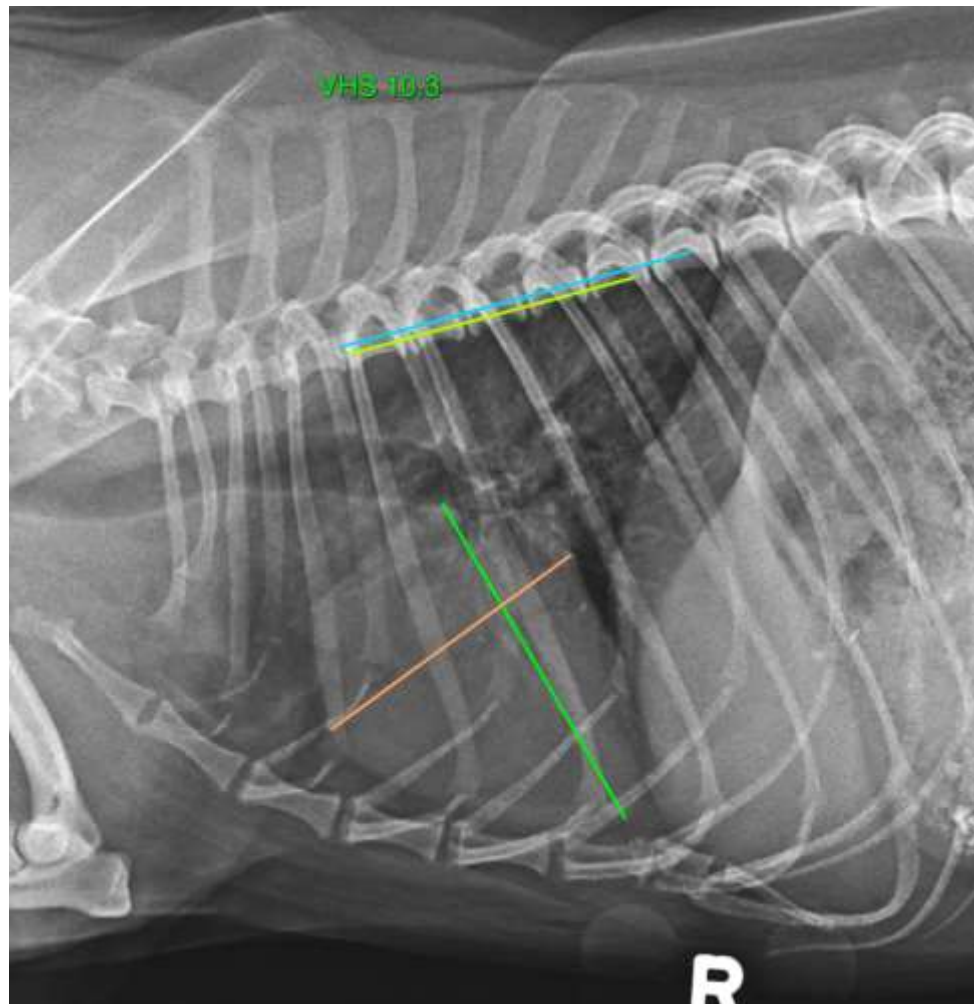
Dr. Britt Dubil

INVOICE

49407

DATE

1-8-22



The information and recommendations provided are based on the images presented by the referring veterinarian. No evaluation can be communicated regarding pathology that was not visible in the image/video clips provided.

Thank you for this referral. If the clinical or image interpretation does not parallel your findings or if I can be of any further assistance please contact me.

Sebastian Schaub, Sebastian Schaub, DVM, Dr. med. vet. DipECVDI
sebast.schaub@gmail.com