



## PATIENT

Bella Northwood

## SPECIES

Canine

## BREED

Terrier x

## SEX

Spayed Female

## AGE

4 Years

## WEIGHT

19.7 lbs

## INTERPRETED BY

Sebastian Schaub, DVM  
Dr. med. vet. DipECVDI

## IMAGING PERFORMED BY

Technician

## HOSPITAL NAME

Paws & Claws Urgent  
Care

## REFERRING VET

Dr. Alexis Rambaud

## INVOICE

73002

## DATE

1/6/26

## PRESENTING CLINICAL SIGNS

Metastatic Thyroid Carcinoma- undergoing chemotherapy. Ct to track progress.

## COMPUTED TOMOGRAPHIC STUDY OF THE NECK & THORAX

A high resolution pre- and post-contrast CT study of the neck and a post-contrast CT study of the thorax is provided for review.

## COMPUTED TOMOGRAPHIC FINDINGS

### Neck

Both temporomandibular joints present congruent joint spaces with even subchondral bone surfaces and are considered within normal limits.

Both tympanic bullae are aerated, the mucosal lining is not seen, the bony wall is smooth and thin. The external ear canals are within normal limits.

The submandibular and medial retropharyngeal lymph nodes are small and elongated with a normal short-to-long-axis-ratio is  $< 0.5$ , the attenuation and contrast enhancement pattern is uniform.

The left thyroid gland is absent. The right thyroid gland has the expected size, shape and attenuation behavior.

### Thorax

The bony and surrounding soft tissue structures are within normal limits.

The sternal, cranial mediastinal and tracheobronchial lymph nodes are small elongated with a normal short-to-long-axis-ratio is  $< 0.5$ , the attenuation and contrast enhancement pattern is uniform and considered within normal limits.

The cardiovascular structures including the pulmonary vasculature are within normal limits.

The bronchial tree presents with regular branching and tapers uniformly towards the periphery as expected, the bronchial walls are thin and smooth. The bronchus-to-artery ratio is within normal limits.

Throughout the lung parenchyma, multiple, randomly distributed, well-defined, soft tissue attenuating nodules are seen; measuring up to 3.7 mm in diameter.

Small incidental gas pockets are seen within the esophageal lumen, there is no evidence of abnormal dilation.

## COMPUTED TOMOGRAPHIC DIAGNOSIS

- History of surgical excision of the left thyroid gland due to thyroid carcinoma
- Structured nodular interstitial lung pattern

## INTERPRETATION OF THE FINDINGS & FURTHER RECOMMENDATIONS

The structured nodular lung pattern is consistent with the history of pulmonary metastatic spread – correlate with preceding radiographic study if the pulmonary metastasis increased in number & size.



## PATIENT

Bella Northwood

## SPECIES

Canine

## BREED

Terrier x

## SEX

Spayed Female

## AGE

4 Years

## WEIGHT

19.7 lbs

## INTERPRETED BY

Sebastian Schaub, DVM  
Dr. med. vet. DipECVDI

## IMAGING PERFORMED BY

Technician

## HOSPITAL NAME

Paws & Claws Urgent  
Care

## REFERRING VET

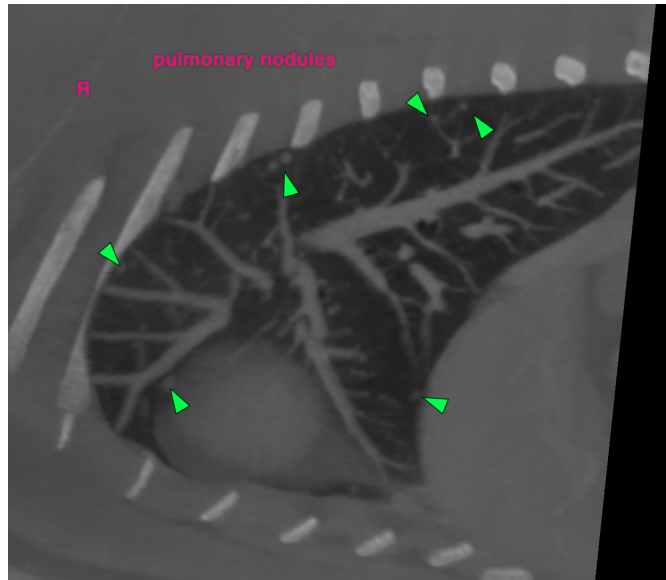
Dr. Alexis Rambaud

## INVOICE

73002

## DATE

1/6/26



The information and recommendations provided are based on the images presented by the referring veterinarian/sonographer. No evaluation can be communicated regarding pathology that was not visible in the image/video clips provided.

Thank you for this referral. If the clinical or image interpretation does not parallel your findings or if I can be of any further assistance please contact me.

**Sebastian Schaub**, DVM, Dr. med. vet. DipECVDI  
[info@sonopath.com](mailto:info@sonopath.com)