



PATIENT PRESENTING CLINICAL SIGNS

PATIENT Chance Bosch
SPECIES Feline
BREED DSH
SEX Neutered Male

History: Presented as a referral, notes from primary DVM on 12/15/2021: Current medications and dose of medications: 1) Theophylline-EOD 2) Prednisolone-1 twist SID 3) Cerenia-1/2 tab SID x 5d off 1 day, then 1/2 tab SID Weight: 11.2 T: 100.6 P: 184 R: 40 BCS: 5/9 Pain Score: 1-2/5 (right side of mouth) Behavior: QAR, Appearance: wnl; Mucous membranes: wnl; pink, moist, CRT < 2 sec Cardiovascular: wnl; no murmur or arrhythmia ausculted, strong synchronous pulses Respiratory: wnl; normal BV sounds t/o all lung fields, can appreciate a ruff/rattling noise referred from upper respiratory Nasal examination: nares free of discharge, unable to appreciate much airflow from the nares but not opening his mouth to breathe Gastrointestinal: wnl; abdomen soft, nonpainful; no overt masses or organomegaly palpable Oral examination: 104 tip fracture, other maxillary PM's/M's severe dental tartar, moderate gingivitis throughout

Abnormal PE/Chem/CBC/UA Results: Chemistry Profile 1/6/22: ALB 4.6 AMY 1150 BUN 36 GLU 161 K+ 3.4

COMPUTED TOMOGRAPHIC STUDY OF THE SKULL

A high-resolution plain CT study of the is provided for review.

AGE COMPUTED TOMOGRAPHIC FINDINGS

16 Years

The tooth element 407 is absent. Parts of the crown of triadan 104 are absent and the pulp cavity is extending up to the surface. Triadan 104 presents advanced resorption of the root and moderate widening of the respective alveolar crest with perforation of the nasal cavity.

INTERPRETED BY

Sebastian Schaub,
 DVM Dr. med. vet.
 DipECVDI

The nasal cavity presents the expected aerated spaces between thin & even conchae and turbinates with smooth mucosal lining.

HOSPITAL NAME

State Avenue VC

Both temporomandibular joints present congruent joint spaces with even subchondral bone surfaces and are considered within normal limits.

Both tympanic bullae are aerated, the mucosal lining is not seen, the bony wall is smooth and thin. The external ear canals are within normal limits.

REFERRING VET

Dr. Raul Casas-Dolz

The submandibular and medial retropharyngeal lymph nodes are small and elongated with a normal short-to-long-axis-ratio is < 0.5, the attenuation pattern is uniform.

COMPUTED TOMOGRAPHIC DIAGNOSIS

INVOICE

13287

- Complicated dental fracture 104
- Periodontal disease and tooth root resorption 104 and oronasal fistula
- Absent 407
- Normal upper airways

DATE

1/6/22

INTERPRETATION OF THE FINDINGS & FURTHER RECOMMENDATIONS



PATIENT

Chance Bosch

The current CT study presents without abnormalities of the upper airways, there is no evidence of obstruction or inflammatory changes. The oronasal fistula of triadan 104 appears not to be associated with rhinitis but extraction of the retained segments of triadan 104 might be beneficial.

SPECIES

Feline

BREED

DSH

SEX

Neutered Male

AGE

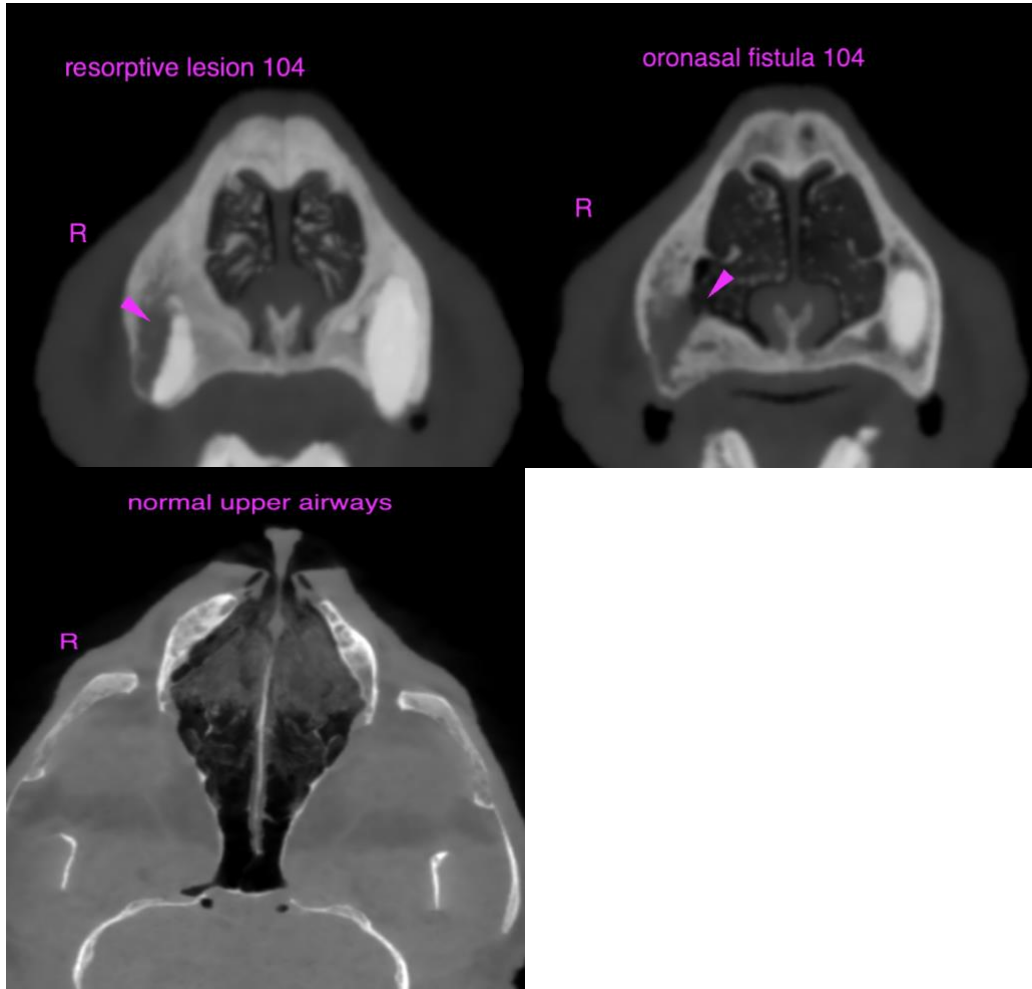
16 Years

INTERPRETED BY

Sebastian Schaub,
DVM Dr. med. vet.
DipECVDI

HOSPITAL NAME

State Avenue VC



REFERRING VET

Dr. Raul Casas-Dolz

The information and recommendations provided are based on the images presented by the referring veterinarian. No evaluation can be communicated regarding pathology that was not visible in the image/video clips provided.

INVOICE

13287

Thank you for this referral. If the clinical or image interpretation does not parallel your findings or if I can be of any further assistance please contact me.

Sebastian Schaub, Sebastian Schaub, DVM, Dr. med. vet. DipECVDI
sebast.schaub@gmail.com

DATE

1/6/22



PATIENT

Chance Bosch

SPECIES

Feline

BREED

DSH

SEX

Neutered Male

AGE

16 Years

INTERPRETED BY

Sebastian Schaub,
DVM Dr. med. vet.
DipECVDI

HOSPITAL NAME

State Avenue VC

REFERRING VET

Dr. Raul Casas-Dolz

INVOICE

13287

DATE

1/6/22