



PATIENT PRESENTING CLINICAL SIGNS

Carmelo Caballero History: Reason for Visit: Limping History: P presents for limping from LH. O states it began yesterday after O was playing with P for a while. O states he was non weight bearing yesterday and today is much better. O did not administer any meds

SPECIES

Canine Abnormal PE/Chem/CBC/UA Results: Hydration: N Mentation: N EENT: N Oral Cavity: N Lymph Nodes: N Skin: N CV/Respiratory: N Abd/GI: N Uro/Perineum: N Musculoskeletal: Weight bearing to slight toe touching lameness left rear. Grade 2-3 bilateral MPL's...both pop when they luxate. No drawer either stifle but mild discomfort on ext of left stifle. Neurological: N

BREED

Boston Terrier

RADIOGRAPHIC STUDY OF THE PELVIS AND STIFLE JOINTS

A ventrodorsal projection of the pelvis and radiographs of the stifle joints in two orthogonal imaging planes are provided for review.

SEX

Neutered Male

RADIOGRAPHIC FINDINGS

There is breed specific malformation of the caudate vertebra.

AGE

2 Years 3 Months

The osseous and surrounding soft tissue structures of the pelvis are within normal limits. The coxofemoral joints present smooth osseous margins and congruent joint space.

The patella of the left stifle joint is superimposed on the medial femoral condyle. The right is in a relative medial position.

INTERPRETED BY

Sebastian Schaub, DVM Dr. med. vet. DipECVDI

Both stifle joints present smooth osseous margins and without signs of intracapsular swelling.

RADIOGRAPHIC DIAGNOSIS

HOSPITAL NAME

DPC VH

- Left sided medial patellar luxation
- Mild medial displacement right patella
- Structural normal pelvis/coxofemoral joints

REFERRING VET

Dr. Feldt

INTERPRETATION OF THE FINDINGS & FURTHER RECOMMENDATIONS

If the medial patellar luxation is the cause of the acute clinical signs is unclear and contusion or distortion need to be ruled out as well. A clinical trial with NSAIDs and might be beneficial in first instance.

INVOICE

13280

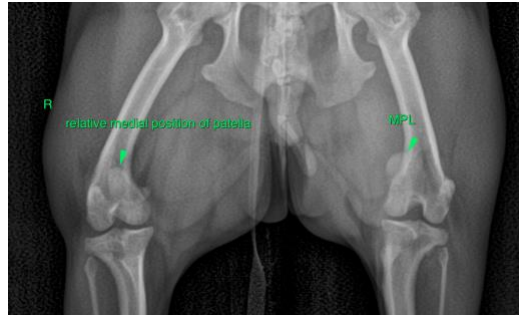
DATE

1/6/22



PATIENT

Carmelo Caballero



SPECIES

Canine

BREED

Boston Terrier

The information and recommendations provided are based on the images presented by the referring veterinarian. No evaluation can be communicated regarding pathology that was not visible in the image/video clips provided.

SEX

Neutered Male

Thank you for this referral. If the clinical or image interpretation does not parallel your findings or if I can be of any further assistance please contact me.

AGE

2 Years 3 Months

Sebastian Schaub, Sebastian Schaub, DVM, Dr. med. vet. DipECVDI
sebast.schaub@gmail.com

INTERPRETED BY

Sebastian Schaub,
DVM Dr. med. vet.
DipECVDI

HOSPITAL NAME

DPC VH

REFERRING VET

Dr. Feldt

INVOICE

13280

DATE

1/6/22