



PATIENT PRESENTING CLINICAL SIGNS

Anakin Greenwald History: Non-weight bearing lameness Left thoracic limb- Swollen limb. Pododermatitis with abscess formation Left fore paw.
Abnormal PE/Chem/CBC/UA Results:

SPECIES

Canine

COMPUTED TOMOGRAPHIC STUDY OF THE THORAX & FRONT LIMBS

A high resolution pre- and post-contrast CT study of the skull and abdomen and a post-contrast CT study of the thorax are provided for review.

BREED

English Bulldog

COMPUTED TOMOGRAPHIC FINDINGS

The mediastinal is significantly widened by fat.

SEX

Intact Male

The sternal, cranial mediastinal and tracheobronchial lymph nodes are small elongated with a normal short-to-long-axis-ratio is < 0.5, the attenuation and contrast enhancement pattern is uniform and considered within normal limits.

AGE

8 Years 3 Months

The cardiovascular structures including the pulmonary vasculature are within normal limits.

The bronchial tree presents with regular branching and tapers uniformly towards the periphery as expected, the bronchial walls are thin and smooth. The bronchus-to-artery ratio is within normal limits.

INTERPRETED BY

Sebastian Schaub,
DVM Dr. med. vet.
DipECVDI

The volume of the lung is mild to moderately decreased and the caudodorsal aspects of the lung parenchyma present regions of compression atelectasis. The right middle lung lobe is consolidated and presents a markedly reduced volume, air-bronchograms are visible.

Small incidental gas pockets are seen within the esophageal lumen, there is no evidence of abnormal dilation.

HOSPITAL NAME

Mobile Pet Imaging

The left axillary lymph node is prominent.

The shoulder joints present smooth osseous margins; the surrounding soft tissue structures are within normal limits. There is an ill-defined subcutaneous swelling, cranial to the left elbow joint. Both elbow joints present advanced osteophyte new bone formation.

REFERRING VET

Meaux

The carpal joints bilaterally are within normal limits.

INVOICE

13276

The soft tissues of the 3rd & 4th digit of the left front limb present a moderate interdigital soft tissue swelling. The osseous structures of both front limbs are within normal limits.

COMPUTED TOMOGRAPHIC DIAGNOSIS

- Subcutaneous swelling, most accentuated region of the left elbow joint

DATE

1/6/22



PATIENT

Anakin Greenwald

- Interdigital swelling left front paw – 3rd & 4th phalanx – history of pododermatitis
- Lymphadenopathy left axillary lymph node
- Advanced degenerative osteoarthritis elbow joints bilaterally
- Significant widening of the mediastinum by fat
- Multiple regions of compression atelectasis of the lung
- Normal shoulder joints
- No evidence of pulmonary metastatic disease

SPECIES

Canine

INTERPRETATION OF THE FINDINGS & FURTHER RECOMMENDATIONS

BREED

English Bulldog

The subcutaneous swelling level with the left elbow joint is most consistent with edema or (septic) steatitis. An underlying cause is not specified in the current CT study, ascending infection by the history of pododermatitis, immunosuppression or perforating wound are considerations. Ultrasound might be beneficial to check if fluid pockets develop, warranting surgical drainage. If there is suspicion for arthritis, a synovial tap including microbial culture appears beneficial.

SEX

Intact Male

No underlying cause for the pododermatitis is appreciated by CT, however ultrasound appears beneficial to screen for foreign material not appreciated by CT.

Reactive hyperplasia of the left axillary lymph node.

AGE

8 Years 3 Months

INTERPRETED BY

Sebastian Schaub,
DVM Dr. med. vet.
DipECVDI

HOSPITAL NAME

Mobile Pet Imaging

REFERRING VET

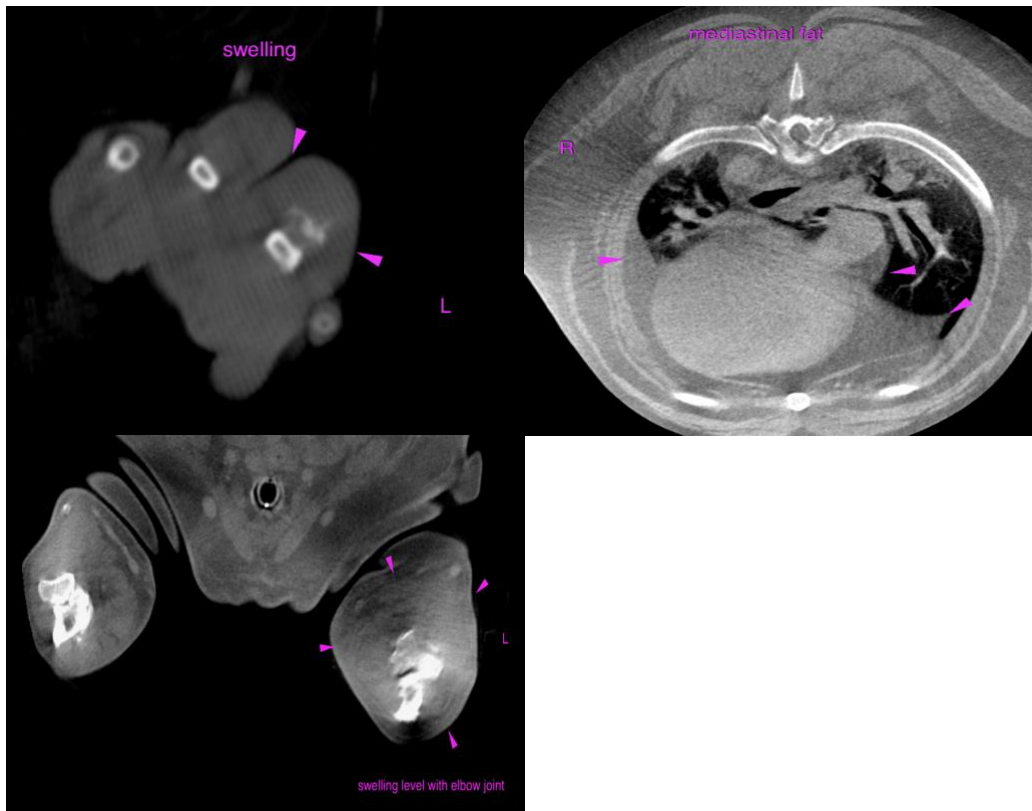
Meaux

INVOICE

13276

DATE

1/6/22





PATIENT

Anakin Greenwald

The information and recommendations provided are based on the images presented by the referring veterinarian. No evaluation can be communicated regarding pathology that was not visible in the image/video clips provided.

SPECIES

Canine

Thank you for this referral. If the clinical or image interpretation does not parallel your findings or if I can be of any further assistance please contact me.

Canine

Sebastian Schaub, Sebastian Schaub, DVM, Dr. med. vet. DipECVDI
sebast.schaub@gmail.com

BREED

English Bulldog

SEX

Intact Male

AGE

8 Years 3 Months

INTERPRETED BY

Sebastian Schaub,
DVM Dr. med. vet.
DipECVDI

HOSPITAL NAME

Mobile Pet Imaging

REFERRING VET

Meaux

INVOICE

13276

DATE

1/6/22