SonoPath Teleradiology

EDUCATIONAL TELECONSULTATION SERVICES™

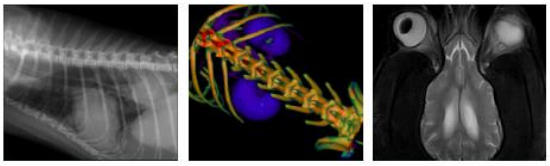

SonoPath.com
1-800-838-4268 info@sonopath.com

PATIENT

Aldo Gemmell

SPECIES

Canine

BREED

Chihuahua

SEX

Neutered Male

AGE

13 Years

INTERPRETED BY

Sebastian Schaub, DVM Dr. med. vet. DipECVDI

HOSPITAL NAME

Sunset AH

REFERRING VET

Dr. Mayra Sanchez

INVOICE

20467

DATE

1/6/23

PRESENTING CLINICAL SIGNS

History: Recent hx of increased panting and snoring No c/s

Abnormal PE/Chem/CBC/UA Results: PE: BCS 6/9, SQ soft masses ventral and lateral thorax

RADIOGRAPHIC STUDY OF THE THORAX

Radiographs of the thorax in three imaging planes are provided for review.

RADIOGRAPHIC FINDINGS

The costal cartilages present moderate degenerative changes.

Multiple fat opaque swelling are seen along the thoracic wall.

The heart is of normal size and shape, there is no evidence of cardiac chamber or vascular enlargement. The pulmonary vasculature is within normal limits.

The cranial mediastinum presents the expected soft tissue opacity. The mediastinal width is less than twice the width of the vertebral column at the same level.

The trachea is normal in diameter and presents the anticipated course. The luminal outline of the trachea is smooth.

The bronchial tree presents with thin walls and tapers uniformly towards the periphery as expected. The lung parenchyma presents the expected architecture and opacity; the intrapulmonary vascular branching is seen up to the third order lung vessels.

The diaphragm is well delineated with even surface and the expected mild cranial bulging of the diaphragmatic cupola.

RADIOGRAPHIC DIAGNOSIS

- History of multiple subcutaneous masses along the thoracic wall – suspect lipomas
- Degenerative changes costal cartilages

INTERPRETATION OF THE FINDINGS & FURTHER RECOMMENDATIONS

The radiographic study presents without abnormalities, explaining the described clinical signs. Rule out upper airway disease as potential source as well.

The crescent shaped soft tissue opacity superimposed on the right lung lobes inconsistently seen on the VD projections is likely caused by a subcutaneous mass.

SonoPath Teleradiology

EDUCATIONAL TELECONSULTATION SERVICES™

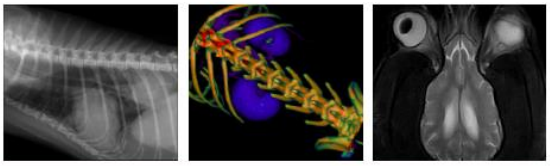

SonoPath.com
1-800-838-4268 info@sonopath.com

PATIENT

Aldo Gemmell

SPECIES

Canine

BREED

Chihuahua

SEX

Neutered Male

AGE

13 Years

INTERPRETED BY

Sebastian Schaub, DVM Dr. med. vet. DipECVDI

HOSPITAL NAME

Sunset AH

REFERRING VET

Dr. Mayra Sanchez

INVOICE

20467

DATE

1/6/23

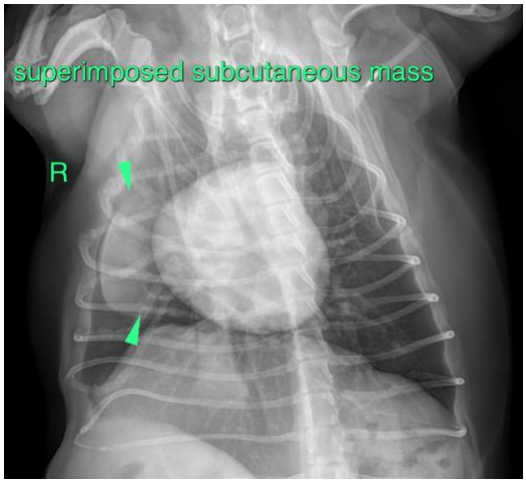

The information and recommendations provided are based on the images presented by the referring veterinarian/sonographer. No evaluation can be communicated regarding pathology that was not visible in the image/video clips provided.

Thank you for this referral. If the clinical or image interpretation does not parallel your findings or if I can be of any further assistance please contact me.

Sebastian Schaub, Sebastian Schaub, DVM, Dr. med. vet. DipECVDI
sebast.schaub@gmail.com