



PATIENT PRESENTING CLINICAL SIGNS

Shayla Lawrence Patient presented to rDVM initially 11/22/22 for unspecified pain. Patient seemed to vocalize when eating, but also would randomly when laying in bed. Bloodwork showed ALP 2090 and mild thrombocytosis. At that time, glucose was 103mg/dL. Patient was sent home with gabapentin and presumptive dx of IVDD. Re-presented on 12/16/22 because owners noted minimal improvement and noticed pain seemed to be isolated to opening of the mouth. Masticatory myositis titers sent out which came back negative. Carprofen was added to the gabapentin. Patient pain continued to worsen. Patient re-presented on 1/3/23 and was noted to have cutaneous draining lesions on caudal dorsum, which had presented over the past week. She is still painful. She is eating and drinking at home with no vomiting or diarrhea. rDVM added clindamycin to treatment protocol.

SPECIES Canine

BREED Dachshund

SEX FS

AGE 12 Years

Abnormal PE/Chem/CBC/UA Results: CBC: No clinically significant abnormalities COMP: Elevated BUN (41.9), hyperphosphatemia(6.3), hyperproteinemia (8.2), hyperglobulinemia (4.3), hypercholesterolemia (>450 but <500 after dilution), elevated ALP (6242 after dilution), hyperglycemia (602 after dilution) with metabolic acidosis, GGT 29, T.bili 0.8 EPOC: Increased 9O2 and cSO2, Decreased pCO2 and bicarbonate, hyperkalemia (6.2), mild hypocalcemia, increased BUN(37), hyperglycemia(627) KETONES: Moderate PCV/TS: 50%, 10g/dL PE: On presentation to us, she is painful with minimal opening of mouth (vocalizes with 30-45 degree opening), has submandibular lymphadenopathy, and swelling in laryngeal exam. She has multiple open draining wounds around rump. She has a heart murmur as well (historical for patient).

COMPUTED TOMOGRAPHY OF THE SKULL, THORAX AND ABDOMEN

A high resolution pre- and post-contrast CT study of the skull and abdomen and a post-contrast CT study of the thorax are provided for review.

INTERPRETED BY

Sebastian Schaub, DVM
Dr. med. vet. DipECVDI

COMPUTED TOMOGRAPHIC FINDINGS

Skull

Multiple teeth are absent. A significant amount of mineral attenuating material is attached to multiple premolar and molar teeth. The teeth present evidence of generalized moderate periodontal disease.

HOSPITAL NAME

Animal Emergency
Hospital Deland

The nasal cavity presents the expected aerated spaces between thin & even conchae and turbinates with smooth mucosal lining.

REFERRING VET

Dr. Schwanebeck

The right tympanic bulla presents a bullous rostral expansion, extending up to the medial aspect of the right ramus of the mandible, distorting the pharynx at the same level. Rostrally the expanded right tympanic bulla is in contact with the ipsilateral temporomandibular joint. The wall of the right tympanic bulla is irregularly thickened with multiple discontinuities. The right tympanic bulla is filled with fluid. The osseous labyrinth of the right inner ear presents signs of osteolysis of the lateral osseous lamella. Mild pressure erosion of the sphenoid bone in contact with the expanded right tympanic bulla is appreciated. The left tympanic bulla contains a small amount of gravity dependent fluid attenuating material, the osseous wall of the left tympanic bulla is smooth and thin.

INVOICE

55995

DATE

1-5-23

Both external ear canals contain a small amount of non-contrast enhancing irregular soft tissue material and the wall of the external ear canal bilaterally is mildly thickened.

The brain presents no deviation from normal anatomy and symmetry. The brain parenchyma is homogeneous and within normal limits for attenuation and distribution of contrast enhancement.



PATIENT The ventricular system is non-dilated and symmetric.

Shayla Lawrence The submandibular and medial retropharyngeal lymph nodes are small and elongated with a normal short-to-long-axis-ratio is < 0.5 , the attenuation and contrast enhancement pattern is uniform.

SPECIES Thorax

Canine The costal cartilages present advanced degenerative changes.

BREED The sternal, cranial mediastinal and tracheobronchial lymph nodes are small elongated with a normal short-to-long-axis-ratio is < 0.5 , the attenuation and contrast enhancement pattern is uniform and considered within normal limits.

Dachshund The cardiovascular structures including the pulmonary vasculature are within normal limits.

SEX The bronchial tree presents with regular branching and tapers uniformly towards the periphery as expected, the bronchial walls are thin and smooth. The bronchus-to-artery ratio is within normal limits.

FS The lung parenchyma presents the expected architecture and attenuation behavior.

AGE Small incidental gas pockets are seen within the esophageal lumen, there is no evidence of abnormal dilation.

12 Years Abdomen

INTERPRETED BY The serosal fat presents normal attenuation behavior. There is no evidence of peritoneal effusion or peritonitis.

Sebastian Schaub, DVM Both kidneys present within normal limits for size, shape and organ architecture. After contrast administration a bilaterally symmetric and uniform nephro- and pyelogram is noted.
Dr. med. vet. DipECVDI

HOSPITAL NAME The adrenal glands are within normal limits for size, shape and organ architecture.

Animal Emergency Hospital Deland The spleen presents with normal shape, even surface, uniformly attenuating parenchyma and homogeneous contrast enhancement, unremarkable.

REFERRING VET The hepatic volume is moderately increased and the liver is protruding caudally beyond the costal arch; the caudoventral hepatic margins are rounded. The hepatic parenchyma is uniform soft tissue attenuating and contrast enhancing. The gastric axis is mildly deviated caudally.

Dr. Schwanebeck The pancreas is evenly contoured, the pancreatic parenchyma is homogeneous and presents uniform contrast enhancement.

INVOICE The position, delineation, wall and content of the gastrointestinal tract are considered within normal limits throughout.

55995 Level with the intervertebral disc space T13/L1, mild irregular mineralized disc material is bulging into the vertebral canal, occupying approximately 30% of the cross-sectional area of the vertebral canal at the same level. The dural tube level T13/L1 is deviated dorsally and distorted.

DATE Multiple intervertebral discs of the lumbar spine present mild central mineralization. Multifocal mild spondylosis formation is seen.

1-5-23



PATIENT

Shayla Lawrence

COMPUTED TOMOGRAPHIC DIAGNOSIS

- Significant expansion and chronic osseous remodeling right tympanic bulla
- Possible right sided otitis interna
- Bilateral otitis externa
- Hepatomegaly
- Intervertebral disc protrusion T13/L1 with compressive myelopathy
- Dental tartar
- Generalized periodontal disease
- Multiple absent teeth
- Multifocal chondroid intervertebral disc degeneration
- Spondylosis deformans
- No evidence of pulmonary metastatic disease

SPECIES

Canine

BREED

Dachshund

SEX

FS

AGE

12 Years

INTERPRETED BY

Sebastian Schaub, DVM
Dr. med. vet. DipECVDI

INTERPRETATION OF THE FINDINGS & FURTHER RECOMMENDATIONS

The main finding is the significant dilation of the right tympanic bulla, the finding is consistent with cholesteatoma due to chronic otitis media. As the lesion is in contact with the right temporomandibular joint and potential focal inflammation are a plausible explanation for the presenting clinical signs. Surgical management either by a ventral bulla osteotomy or right sided total ear canal ablation and lateral bulla osteotomy appears beneficial – trying to remove as much as possible from the epithelial lining of the expanded tympanic bulla.

Potentials for the hepatomegaly include metabolic hepatic disease, hepatitis or diffuse neoplastic infiltration. In case of doubt, ultrasound guided FNA sampling and/or Tru-cut biopsy can be used as minimally invasive methods for further workup.

The intervertebral disc protrusion T13/L1 is considered chronic but can be a cause for intermittent spinal pain.

HOSPITAL NAME

Animal Emergency
Hospital Deland

REFERRING VET

Dr. Schwanebeck

INVOICE

55995

DATE

1-5-23



PATIENT

Shayla Lawrence

SPECIES

Canine

BREED

Dachshund

SEX

FS

AGE

12 Years

INTERPRETED BY

Sebastian Schaub, DVM
Dr. med. vet. DipECVDI

HOSPITAL NAME

Animal Emergency
Hospital Deland

REFERRING VET

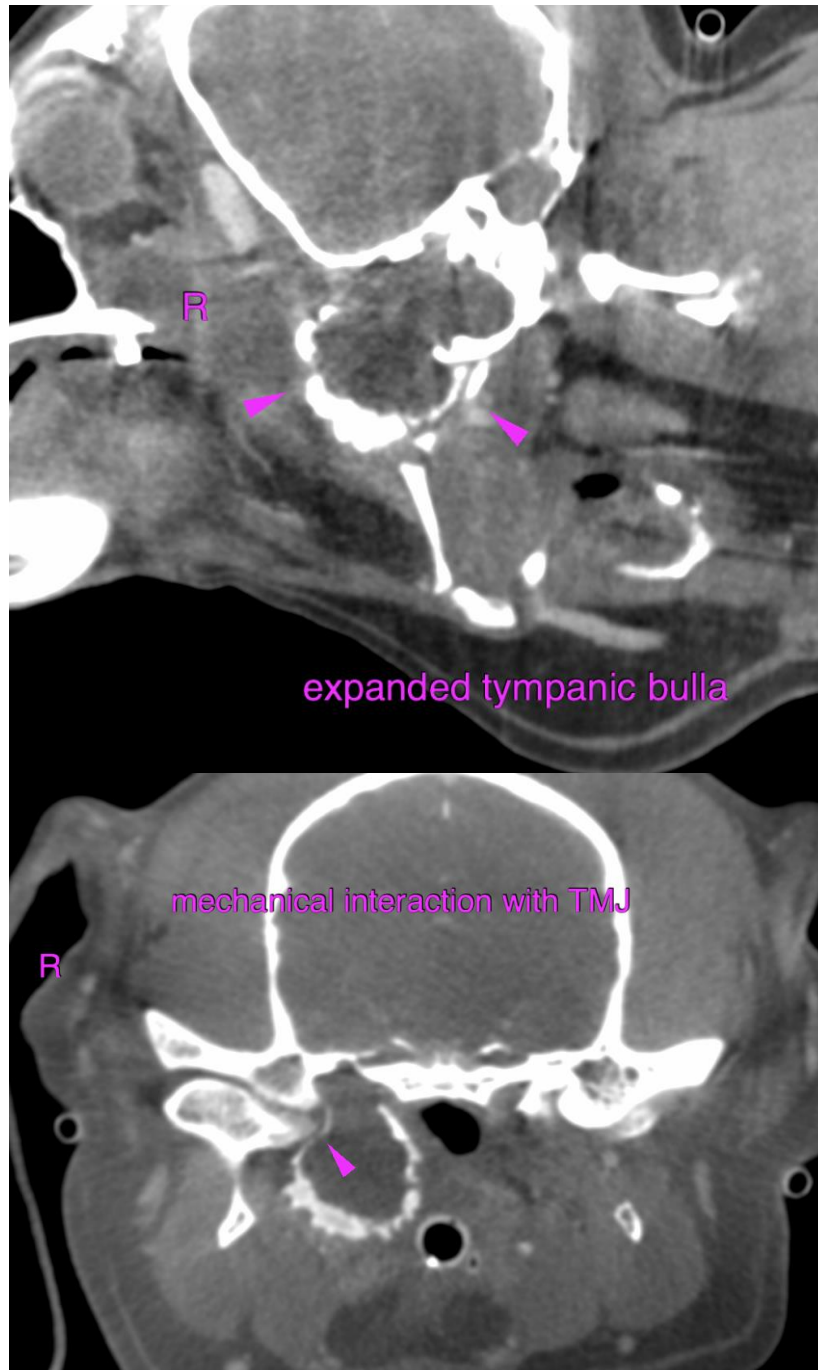
Dr. Schwanebeck

INVOICE

55995

DATE

1-5-23





PATIENT

Shayla Lawrence

SPECIES

Canine

BREED

Dachshund

SEX

FS

AGE

12 Years

INTERPRETED BY

Sebastian Schaub, DVM
Dr. med. vet. DipECVDI

HOSPITAL NAME

Animal Emergency
Hospital Deland

REFERRING VET

Dr. Schwanebeck

INVOICE

55995

DATE

1-5-23

The information and recommendations provided are based on the images presented by the referring veterinarian/sonographer. No evaluation can be communicated regarding pathology that was not visible in the image/video clips provided.

Thank you for this referral. If the clinical or image interpretation does not parallel your findings or if I can be of any further assistance please contact me.

Sebastian Schaub, Sebastian Schaub, DVM, Dr. med. vet. DipECVDI
sebast.schaub@gmail.com