



**PATIENT PRESENTING CLINICAL SIGNS**

Brady Reilly Exophthalmos OD

**COMPUTED TOMOGRAPHY OF THE SKULL & THORAX**

**SPECIES** A high resolution pre- and post-contrast CT study of the skull and a post-contrast CT study of the thorax are provided for review.

Canine

**COMPUTED TOMOGRAPHIC FINDINGS**

**BREED** Skull

Poodle Multiple teeth are absent. The remaining teeth present evidence of moderate periodontal disease

The nasal cavity presents the expected aerated spaces between thin & even conchae and turbinates with smooth mucosal lining.

**SEX**

Intact Male

In the caudal aspect of the right orbita in broad contact with the caudomedial wall of the right orbit, an expansile mass with amorphous mineralization is seen, measuring approximately 4.0 x 3.2 x 4.4 cm in size. The right ocular bulb is deviated rostrally by the mass effect. The medial wall of the right orbit presents zones with aggressive osteolysis, perforating the cranial fossa. The sphenoid bone, right zygomatic arch and ramus of the mandible present advanced permeative osteolytic lesions.

**AGE**

8 Years

Both temporomandibular joints present congruent joint spaces with even subchondral bone surfaces and are considered within normal limits.

Both tympanic bullae are aerated, the mucosal lining is not seen, the bony wall is smooth and thin. The external ear canals are within normal limits.

**INTERPRETED BY**

Sebastian Schaub, DVM  
Dr. med. vet. DipECVDI

The brain presents no deviation from normal anatomy and symmetry. The brain parenchyma is homogeneous and within normal limits for attenuation and distribution of contrast enhancement. The ventricular system is non-dilated and symmetric.

**HOSPITAL NAME**

Mobile Pet Imaging

The mandibular lymph nodes are prominent.

Thorax

The bony and surrounding soft tissue structures are within normal limits.

**REFERRING VET**

Meaux

The sternal, cranial mediastinal and tracheobronchial lymph nodes are small elongated with a normal short-to-long-axis-ratio is < 0.5, the attenuation and contrast enhancement pattern is uniform and considered within normal limits.

The cardiovascular structures including the pulmonary vasculature are within normal limits.

**INVOICE**

56028

Multifocal throughout the lung parenchyma, well-defined soft tissue attenuating nodules with variable degree of mineralization are appreciated, measuring up to 7 mm in size.

Small incidental gas pockets are seen within the esophageal lumen, there is no evidence of abnormal dilation.

**DATE**

1-5-23

**COMPUTED TOMOGRAPHIC DIAGNOSIS**

- Large mineralizing mass right orbit with polyostotic aggressive osteolytic lesions and perforation of the cranial fossa



- PATIENT**
- Secondary right sided exophthalmos
  - Structured nodular interstitial lung pattern with mineralization
- Brady Reilly
- Lymphadenopathy mandibular lymph nodes
  - Multiple absent teeth

**SPECIES INTERPRETATION OF THE FINDINGS & FURTHER RECOMMENDATIONS**

Canine The right retrobulbar mass is suggestive for primary osseous neoplasm, such as osteosarcoma or chondrosarcoma, with pulmonary metastatic spread. The odds for reactive hyperplasia or metastatic spread to the mandibular lymph nodes are considered equal. FNA sampling ± biopsy can be used for further differentiation. Treatment options are limited to palliative management.

**BREED**

Poodle

**SEX**

Intact Male

**AGE**

8 Years

**INTERPRETED BY**

Sebastian Schaub, DVM  
Dr. med. vet. DipECVDI

**HOSPITAL NAME**

Mobile Pet Imaging

**REFERRING VET**

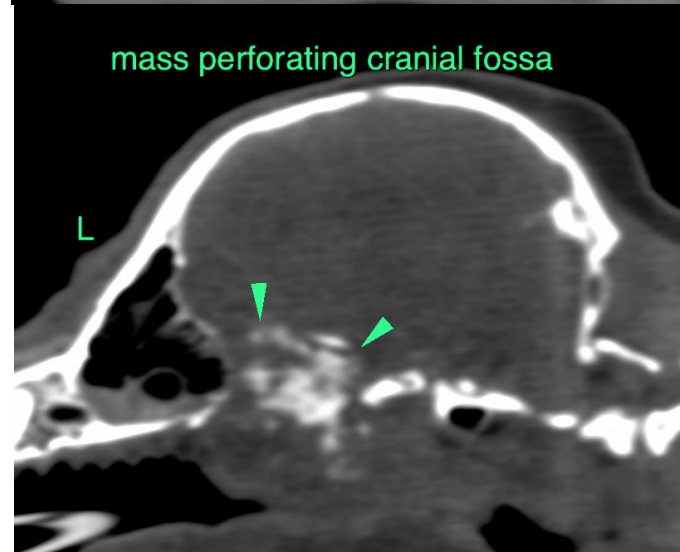
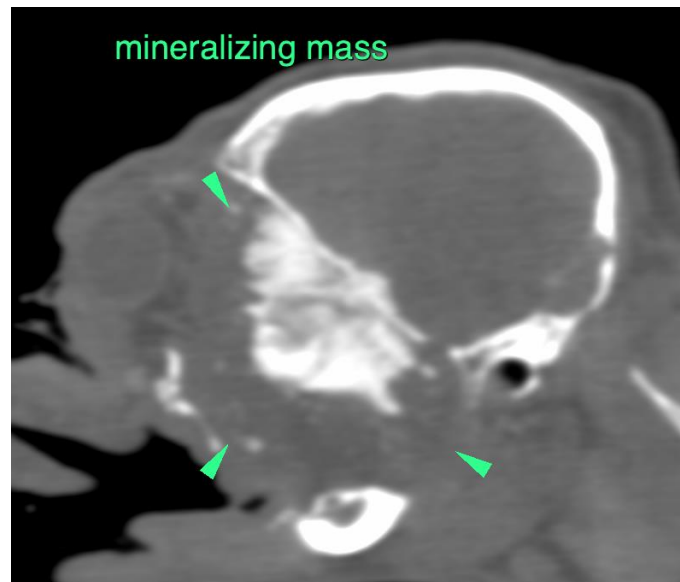
Meaux

**INVOICE**

56028

**DATE**

1-5-23





**PATIENT**

Brady Reilly

**SPECIES**

Canine

**BREED**

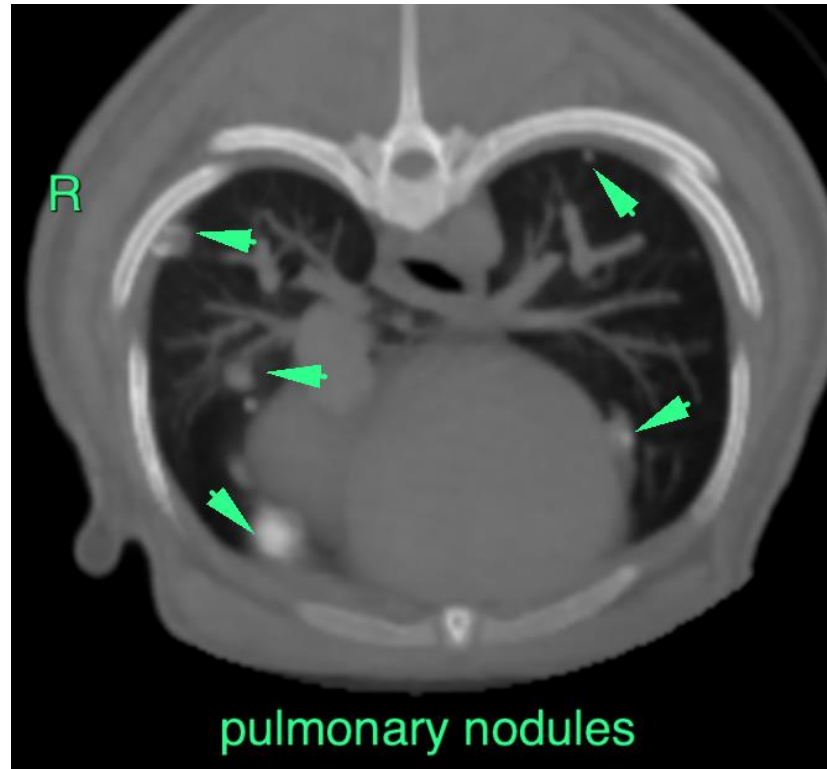
Poodle

**SEX**

Intact Male

**AGE**

8 Years



**INTERPRETED BY**

Sebastian Schaub, DVM  
Dr. med. vet. DipECVDI

The information and recommendations provided are based on the images presented by the referring veterinarian/sonographer. No evaluation can be communicated regarding pathology that was not visible in the image/video clips provided.

**HOSPITAL NAME**

Mobile Pet Imaging

Thank you for this referral. If the clinical or image interpretation does not parallel your findings or if I can be of any further assistance please contact me.

**REFERRING VET**

Meaux

**Sebastian Schaub**, Sebastian Schaub, DVM, Dr. med. vet. DipECVDI  
sebast.schaub@gmail.com

**INVOICE**

56028

**DATE**

1-5-23