



PATIENT PRESENTING CLINICAL SIGNS

Bandit Lowe Had 2 seizures in 2 weeks last month. Yesterday had 4 over the course of 24 hours.
Abnormal PE/Chem/CBC/UA Results: Albumin 4.4 g/dL, glucose 180mg/dL

SPECIES COMPUTED TOMOGRAPHY OF THE SKULL

Canine A pre- and post-contrast CT study of the skull in a bone and soft tissue reconstruction is provided for review.

COMPUTED TOMOGRAPHIC FINDINGS

BREED The pictured parts of the dentition are complete and unremarkable in all jaw quadrants.

Cur The nasal cavity presents the expected aerated spaces between thin & even conchae and turbinates with smooth mucosal lining.

SEX Both temporomandibular joints present congruent joint spaces with even subchondral bone surfaces and are considered within normal limits.

MN Both tympanic bullae are aerated, the mucosal lining is not seen, the bony wall is smooth and thin. The external ear canals are within normal limits.

AGE The brain presents no deviation from normal anatomy and symmetry. The brain parenchyma is homogeneous and within normal limits for attenuation and distribution of contrast enhancement. The ventricular system is non-dilated and symmetric.

4 Years

INTERPRETED BY The submandibular and medial retropharyngeal lymph nodes are small and elongated with a normal short-to-long-axis-ratio is < 0.5, the attenuation and contrast enhancement pattern is uniform.

Sebastian Schaub, DVM
Dr. med. vet. DipECVDI

COMPUTED TOMOGRAPHIC DIAGNOSIS

- Normal skull
- Structural normal brain

HOSPITAL NAME

Bluegrass Veterinary Specialists

INTERPRETATION OF THE FINDINGS & FURTHER RECOMMENDATIONS

In the present study of the brain there is no evidence of macromorphological disease, which supports the presumptive diagnosis of idiopathic epilepsy.

REFERRING VET

Roan

If not yet done so, the workup should be complemented by examination of CSF and complete bloodwork to screen for brain disease that is not necessarily associated with structural changes of the brain parenchyma and rule out hepatoencephalopathy and other systemic illness. In case of the strong clinical suspicion of structural intraparenchymal changes an MRI may be considered.

INVOICE

56033

DATE

1-5-23



PATIENT

Bandit Lowe

SPECIES

Canine

BREED

Cur

SEX

MN

AGE

4 Years

INTERPRETED BY

Sebastian Schaub, DVM
Dr. med. vet. DipECVDI

HOSPITAL NAME

Bluegrass Veterinary
Specialists

REFERRING VET

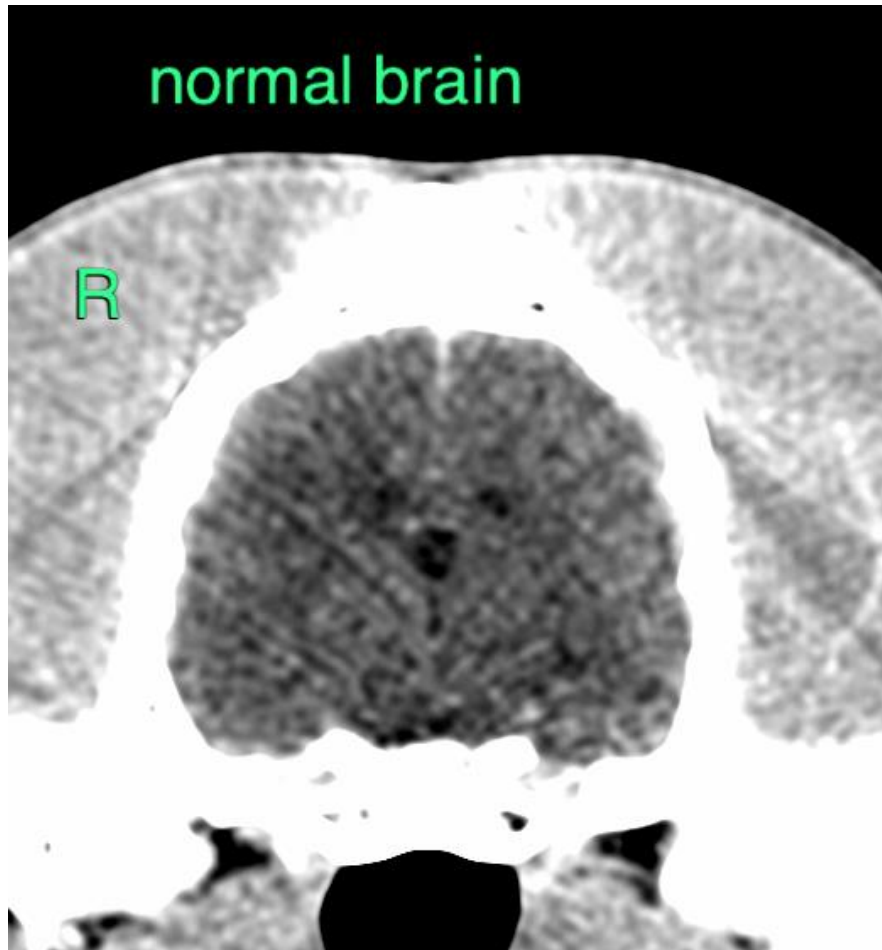
Roan

INVOICE

56033

DATE

1-5-23



The information and recommendations provided are based on the images presented by the referring veterinarian/sonographer. No evaluation can be communicated regarding pathology that was not visible in the image/video clips provided.

Thank you for this referral. If the clinical or image interpretation does not parallel your findings or if I can be of any further assistance please contact me.

Sebastian Schaub, Sebastian Schaub, DVM, Dr. med. vet. DipECVDI
sebast.schaub@gmail.com