



PATIENT PRESENTING CLINICAL SIGNS

Sweeties-Lumi-Giarrusso
 History: Sweeties presented for: Abnormal vulvar area. She is a recent foundling. No microchip. She has been eating/drinking, urinating and defecating. She was seen by RDVM 2 days ago (11/05/21) , given Convenia, sent with Baytril 68 mg and Carprofen 25 mg. Sweeties had a cystoscopy shortly after the CT scan and an ectopic ureter was found. Sweeties is currently being treated for Klebsiella.

SPECIES Abnormal PE/Chem/CBC/UA Results:

Canine **COMPUTED TOMOGRAPHIC STUDY OF THE ABDOMEN**

A high-resolution post-contrast CT study of the abdomen is provided for review.

BREED
COMPUTED TOMOGRAPHIC FINDINGS

Poodle Mix
 The serosal fat presents normal attenuation behavior. There is no evidence of peritoneal effusion or peritonitis.

SEX
 Female
 Both kidneys present within normal limits for size, shape and organ architecture. The left renal pelvis is moderately dilated, measuring approximately 13 mm in width. The left ureter is significantly distended, measuring up to 15 mm in diameter. The left ureter takes a tortuous course caudally and can be followed into the pelvic canal. Within the pelvic canal the left ureters tapers and cannot be appreciated anymore – likely merges with the urinary bladder neck/urethra. Contrast is appreciated in the urethra and vulva.

AGE
 5 Years
 The right ureter presents with a normal diameter, but segmental mild saccular dilation in the most distal segment.

INTERPRETED BY
 Sebastian Schaub,
 DVM Dr. med. vet.
 DipECVDI
 The urinary bladder is mildly distended by contrast media. The urinary bladder wall is moderately thickened – likely accentuated by the filling status – measuring up to 7 mm in width. The level of the right ureteral orifice cannot be specified.

HOSPITAL NAME The adrenal glands are within normal limits for size, shape and organ architecture.

Critical VC/Suncoast
 Veterinary
 Both liver and spleen present with normal shape, even surface, uniformly attenuating parenchyma and homogeneous contrast enhancement, unremarkable.

REFERRING VET The position, delineation, wall and content of the gastrointestinal tract are considered within normal limits throughout.

Dr. Young The bony and surrounding soft tissue structures reveal no abnormalities.

INVOICE **COMPUTED TOMOGRAPHIC DIAGNOSIS**

- 13274
- Left sided ureteral ectopia
 - Left sided moderate pyelectasia

DATE

1/5/22



PATIENT

Sweeties-Lumi-Giarrusso

- Left sided hydroureter
- Suspect small pulsation diverticulum right ureter
- Suspect cystitis

INTERPRETATION OF THE FINDINGS & FURTHER RECOMMENDATIONS

SPECIES

Canine

The findings support the diagnosis of at least left sided ureteral ectopia with secondary hydroureter and pyelectasia – likely due to increased resistance and potential scending infection. Surgical management is the therapy of choice.

BREED

Poodle Mix

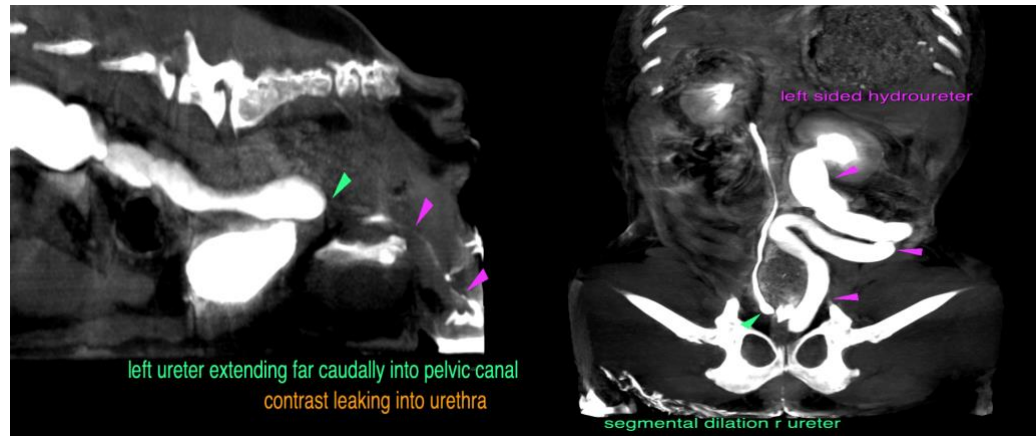
The segmental mild saccular dilation of the right ureter is considered an incidental finding, however as the level of the right ureteral orifice cannot be appreciated, rule out relative caudal termination of the right ureter as well.

SEX

Female

AGE

5 Years



INTERPRETED BY

Sebastian Schaub, DVM Dr. med. vet. DipECVDI

The information and recommendations provided are based on the images presented by the referring veterinarian. No evaluation can be communicated regarding pathology that was not visible in the image/video clips provided.

HOSPITAL NAME

Critical VC/Suncoast Veterinary

Thank you for this referral. If the clinical or image interpretation does not parallel your findings or if I can be of any further assistance please contact me.

Sebastian Schaub, Sebastian Schaub, DVM, Dr. med. vet. DipECVDI
sebast.schaub@gmail.com

REFERRING VET

Dr. Young

INVOICE

13274

DATE

1/5/22



PATIENT

Sweeties-Lumi-
Giarrusso

SPECIES

Canine

BREED

Poodle Mix

SEX

Female

AGE

5 Years

INTERPRETED BY

Sebastian Schaub,
DVM Dr. med. vet.
DipECVDI

HOSPITAL NAME

Critical VC/Suncoast
Veterinary

REFERRING VET

Dr. Young

INVOICE

13274

DATE

1/5/22